The ABC Handbook of







Ringside Medicine





July, 2011

HANDBOOK OF RINGSIDE MEDICINE



August, 2011

CONTRIBUTORS:

Julian E. Bailes, M.D.
Anthony Curreri, M.D.
Mariel Eliza, M.D.
Alan Freedman, M.D.
Barry Jordan, M.D.
Michael Kelly, D.O.
Anthony Petraglia, M.D.
Sheryl Wulkan, M.D.
Eric Wurmser, M.D.
Bruce Zagelbaum, M.D.

TABLE OF CONTENTS

1. SECTION 1 ..... Forward
2. SECTION 2 ..... Introduction
3. SECTION 3 ..... Overview
4. SECTION 4 ..... Infectious Diseases
5. SECTION 5 ..... Neurology
6. SECTION 6 ..... Ophthalmology
7. SECTION 7 ..... Orthopedics
8. SECTION 8 ..... Facial Lacerations
9. SECTION 9 ..... Self- Assessment
10. SECTION 10 ..... ABC Medical Forms
11. SECTION 11 ..... Therapeutic Use Exemption Forms
12. SECTION 12 ..... Acknowledgements

FORWARD

It is rare to be afforded the opportunity to work with so many morally centered, intellectually gifted and motivated individuals, all dedicated to a similar cause,
in the span of one's lifetime. Contributors to this year's endeavors included more than 40 such medical committee members hailing from a wide array of ABC jurisdictions and an equally wide array of medical specialties and industry related professions. These individuals dedicated an unprecedented amount of time and energy to a project that culminated in the production of both the ABC Medical Committee's *Suggested Guidelines for Commissioners* handbook and the *ABC Ringside Physician's Medical Handbook*. We hope you find our recommendations useful, and continue to utilize this committee as a resource for your medical questions and conundra.

Over the past year, we have witnessed a subtle shift in the mentality of various industry factions; rather than working independently and surreptitiously toward seemingly disparate goals, commissioners, judges, referees, promoters, coaches, combat sports participants and ringside physicians have all begun to appreciate and to depend upon each group's area of expertise, while continuing to respect each other's individual roles, responsibilities, and long and short term objectives and motivations.

It is our hope that all combat sports participants will benefit from the continuous exchange of ideas, as we consistently strive to find, and to refine, new and innovative ways to easily access and share knowledge about health and safety issues affecting combat sports athletes.

Special thanks to Tim Lueckenhoff, ABC President, for his unprecedented energy and support, and his patience when fielding all my questions.
Special thanks to Dr. Edgar Ballenas and Dr. Peter Q. Warinner for producing a very successful, entertaining and informative webinar
Special thanks to Drs. Julian Bailes, Barry Jordan, Anthony Curreri, Alan Freedman, Michael Kelly, Anthony Petraglia, and Bruce Zagelbaum for their contributions to the *ABC Ringside Physician's Medical Handbook.*

Thanks to all Committee members once again for your participation, dedication and hard work.

I hope that every committee member has benefited, both personally and professionally from this past year's endeavors, as much as have I.

Respectfully,

Sheryl L Wulkan, MD.

Sheryl Wulkan, M.D.

ABC Medical Chair*

July 7, 2011

**The recommendations in these handbooks are based on present day knowledge. They should be revised approximately every two years as research and technology provide the industry with newer, more prescient information.*

INTRODUCTION

Ringside medicine is one of the most enjoyable and rewarding, but also one of the more challenging facets of sports medicine. It is also, arguably, one of the more intellectually difficult and physically demanding sports medicine sub-specialties. Its practitioners need to be well versed in emergency medicine, internal medicine, orthopedics, and in several aspects of neurology, ophthalmology and infectious diseases. Triage skills are of paramount importance. Above all, the ability to maintain one's composure and to stay the power of one's convictions under the auspices of promoter pressure and / or public scrutiny, whether it be at a smaller, amateur event or a large HBO or pay-per view event, is imperative.

Bear in mind that this handbook merely provides the nidus on which to build a strong information base. Further information should be garnered from ABCmedinfonet.com, the official ABC medical committee website. Information portals will be available for all interested physicians effective January 1, 2012. Webinars will be given, free of charge, approximately four times per year by noted authorities. Further information may be obtained by contacting your jurisdiction's Athletic Control Board, by obtaining one of several excellent, commercially available ringside medicine textbooks, or by submitting questions directly to the ABC Medical Committee at: medcomm@abcmedinfonet.com or swulkan@abcmedinfonet.com.

An Overview of Ringside Medicine

Contributors:
Author: Sheryl Wulkan, M.D.
ABC Medical Chair
Edited by Louis Gleckel, M.D.

PRE-PARTICIPATION CLEARANCE REQUIREMENTS

There are currently no unified medical requirements for pre-participation clearance of combat sports participants. In fact, some jurisdictions do not have physicians as Commission participants/advisors. It is the present consensus of the ABC medical committee that the following MINIMUM requirements be obtained and reviewed for every combat sports participant. (Addendum I). Please note that these standards have not yet been voted upon by the ABC membership. Therefore, you will need to familiarize yourself with your jurisdiction's current requirements, and determine for yourself whether you believe you have enough medical background on each competitor to feel comfortable clearing them for competition. Understand that fight night is NOT the right time to find out a competitor has a history of hemodynamically significant palpitations, or a loud, but perhaps insignificant murmur, has had corrective eye surgery, but he/she can't recall the name of the procedure, is taking stimulants for treatment of ADD, or that he/she is on hormone replacement. There is no time to tease out the truth at that point; you will be under tremendous pressure to " let the fight go", and you will have unwittingly placed yourself, and your jurisdiction, in a precarious moral and medical dilemma by taking the chance that nothing bad will happen to the competitor during the bout relating to this newly acquired information. You may get away with that approach for awhile, but if you sit ringside long enough, that attitude, coupled with statistics and the laws of probability, will come back to haunt you. You need to make your decisions based on sound factual bases.

The ABC medical committee has designed medical forms and waiver sheets that it hopes will be adopted by most member jurisdictions for use. PLEASE NOTE: the ABC membership will be voting to decide on the unification of forms, use of TUE's, etc. at the August 1-3 Annual Convention in Washington DC. Please go to the ABC website, or contact your Commission for the most recent status.

FIGHT NIGHT

PRE-FIGHT PHYSICALS:

Pre-fight physicals are the astute ringside physician's time to evaluate each participant's mental, physical and emotional baseline. Emphasis should be placed on a thorough review of systems, with particular focus placed on the neurologic, ophthalmologic, cardiovascular and orthopedic aspects of this review. Remember to include questions pertaining to body piercings, caps or veneers, weight cutting, eye surgery, allergies to latex gloves, family history of sudden death and congenital abnormalities. It is also important to include a complete concussion history, since combat sports athletes often give responses that are sports specific only. Concussions obtained in street or bar fights are relevant. The orthopedic, neurologic and ophthalmologic examinations should be emphasized during the pre-fight physical. Remember that the ophthalmologic examination should include a test of peripheral vision. A complete physical should take an experienced practitioner no more than 2-3 minutes providing pre-participation medicals had been submitted, reviewed and accepted by your jurisdiction's lead physician(s). The pre-fight examination should clearly be more extensive if your jurisdiction only requires fight-night physicals. Be cognizant of the fact that the ABC

medical committee does not support this policy.

INTRODUCTIONS:

Introduce yourself to the inspectors, referees, and security staff. Let them know what methods of communication you will use to voice concern, if any, during a bout, and how you would prefer to get their attention in case of emergency. Inform all staff of your accessibility regarding their observations and concerns during the event. A team approach instills confidence and security, and is the best way to maximize the potential for a safe show. Communication and open dialogue also ensure that everyone has an idea of his, her role in the event of a problematic bout.

AMBULANCE:

At least one ambulance MUST be on location at the venue, but two are preferable; otherwise, the show must be stopped in the event an injured athlete requires transport to the hospital. The ambulance crew should be made aware of how the lead physician runs his/her code team. The physician should also inform the ambulance crew as to what equipment need be placed ringside (collar, oxygen, adult mask, board). The ringside doctors and the medics should do a "walk through" of the venue's evacuation route. If an elevator is part of the plan, the medical staff should make sure that it's functioning, that it has been designated for the sole purpose of evacuating an injured athlete, and that it is large enough to accommodate both a stretcher and accompanying medical personnel.
The chief ringside physician should have the telephone number of both the trauma center and the nearest hospital (if they are not the same) on his/her speed dial. The hospital(s) and neurosurgeon on call should be notified about the event prior to its onset. If an event is occurring in a more remote location, consideration must be made for alternatives to ground transport (helicopter). Neurosurgeons may not be on site at some hospitals, so it is imperative that they be notified THE DAY BEFORE THE EVENT.

INSURANCE:

It is important to determine whether your insurance covers out-of- office activities, or whether a malpractice rider is required. Some jurisdictions cover physician malpractice; make sure you familiarize yourself with the rules of your commission.

EQUIPMENT REQUIREMENTS:

The ABC medical committee recommends as its minimum suggested on site medical equipment:

Stethoscope.
Blood pressure cuff.
Gloves (preferably nitrile).

Ophthalmoscope.

Penlight.
Gauze

Steri-strips
Bacitracin or Neosporin
Hazardous material waste bags

Complete ACLS set to be supplied by the Commission and maintained by the Chief Ringside physician

Air casts or SAM casts
Tape
Scissors
Tracheotomy set

Medicine.
Epinephrine (cardiac doses)
Short acting B blocker
Tylenol
Epinephrine (1/1000), Avitene and/ or thrombin
Adenosine
The ringside physician should bring several complete suture kits to the venue if his/her jurisdiction permits suturing on site.

THE EVENT:

Injuries such as lacerations and orbital swelling often occur during a bout. The referee may ask you to evaluate a fighter's injury to assess whether the contest need be stopped. Similarly, the doctor may signal the referee about concerns he/she may have about a contestant, such as fatigue, lack of use of a dominant hand, etc. It is therefore imperative that you familiarize yourself with the locations of significant facial lacerations. In the event of significant orbital swelling, it is imperative to evaluate the fighter's ability to see sufficiently clearly, to determine whether his/her extraocular eye movements are intact and to identify whether his/her peripheral vision differs significantly from the pre-fight physical. Expect to be booed and to be met with fighter objections if you believe the fight needs to be stopped. Remember, your job is to ensure fighter safety, not to please the crowd.

An essential tool of the ringside physician is his/her familiarity with a Quick Fighter Assessment. This should start while you sit ringside, so that you have a working differential diagnosis and treatment plan in mind before the referee calls you in for a more official assessment of an injury. This way you have a heightened awareness of the potential seriousness of an injury should the fighter be unable to continue his/her match.

Questions involved in a rapid evaluation include:

1. How well is the fighter defending him/herself? Is he/she using all her weapons?
2. How worried do the corner men seem?
3. Has the fighter's gait changed?
4. Do the fighter's eyes seem focused, or is he/ she "running on instinct"?

- What the ringside physician should be thinking: Is the inability to focus due to fatigue or something more serious, like a concussion? A concussed fighter's eyes may tear due to stimulation of the lacrimal glands.

The ringside physician may be asked by the referee to evaluate a fighter for his/ her ability to continue a bout. Sometimes, in the amateurs, opponents are highly mismatched, and one way for a referee to help a fighter "save face" is to allow a doctor to stop the bout for medical reasons. Whether amateur or pro, you should not hesitate to evaluate a fighter between rounds for his/her ability to continue a bout if you are

worried about concussion or other serious injuries having occurred.

If called into the ring or cage to assess a fighter for his ability to continue post knock - down, a rapid neurologic assessment can be accomplished using the following concepts...(these may also be used as part of the post-fight physical examination):

1. The competitor should be asked whether he/she feels capable of continuing the bout. Hesitation in response to this question may indicate that a fighter is injured, but may not want to disappoint his corner or fans. Uninjured fighters make direct eye contact with the examining physician, and rarely hesitate when answering questions. Failure to do so may be an indication to stop the fight.

2. How quickly does the fighter respond to questions? Are the responses accurate? An inability to answer questions about the fight, such as the name of the fighter's trainer, the name of the venue, the location of the venue, or his opponent's name may be indicative of memory impairment or difficulty concentrating from a concussion or bleed.

3. Is the fighter ataxic?
Balance disturbances may indicate a concussion.

4. Do the fighter's eyes seem focused on you and what's happening in his/her surroundings? Do the eyes appear glassy?
A concussion can cause a fighter to appear dissociated from his/her surroundings and causes secretion from the lacrimal glands resulting in a glassy - eyed appearance.

POST FIGHT:

The post-fight physical should include a brief neurologic, orthopedic, cardiovascular and ophthalmologic assessment. The competitor's gloves should be removed prior to evaluation. A fighter may be examined while exiting the ring or cage in the event there is only one ringside physician assigned to the show. Ideally, the participant should be examined in a designated quiet area. The corner should be notified when the ringside physician desires a second post- fight examination for specific concerns that may be rectified over a time of observation prior to post-fight clearance. A medic or a physician should remain with the fighter of concern at all times until the standards for the post-fight examination have been attained.

ADDENDUM: Suggested Minimum Ringside Physicians' Requirements

A. Background

- Must be M.D.s or D.O.s
- Must be licensed and in good standing
- Should have some familiarity with sports medicine and combat sports
- Suggested specialties: Emergency medicine, Sports Medicine, Internal Medicine, Family Practice, Neurosurgery, Ophthalmology, Neurology, Plastic Surgery or any other Primary Care specialty with emergency medical care experience.
- Current ACLS and/or ATLS certification
- Apprenticeship with a Commissioned Ringside Physician for a minimum of three to four shows. It is recommended that apprenticeship be allowed to occur in ay jurisdiction represented at the ABC if a given member has too few shows annually to meet the minimum apprenticeship requirement.
- INDIVIDUAL PROMOTIONS SHOULD NOT BE ALLOWED TO BRING THEIR OWN PHYSICIANS FOR AN EVENT.
- Physicians acting as ringside doctors should be made aware of the medical liabilities of their jurisdiction and should addend their medical malpractice coverage accordingly.
- We recommend re-emphasizing the tacit understanding that all medical decisions made by ringside physicians remain untainted by the size of the promotion or its sponsors, television rights, or the popularity of an athlete.

B. Minimum Medical Equipment Requirements Fight Night

- Stethoscope
- Sphygmomanometer
- Otoscope
- (Vision card)*
- Flashlight
- Gloves
- Gauze
- Tape and Scissors
- Sam casts, air casts
- ACLS kit
- AED

- to be used to grossly assess whether an injured fighter can see: not to define his/her actual visual acuity during a bout
-

C. Minimum Suggested Pre-Participation Medical Clearance Requirements

- H.I.P.A.A. release form to include access to medical records if hospitalized.
- A cover letter for providers doing pre-participation clearance physicals explaining the details of conditions found more frequently in combat sports athletes.
- Dilated eye examination performed by an ophthalmologist.
- Pre-fight physical.
- MRI/MRA of the head. (preferable to head CT)
- Screening serology for HIV, hepatitis B and hepatitis C
- Baseline EKG.

Infectious Diseases in Ringside Medicine

Contributor:
Sheryl Wulkan, M.D., Chair, ABC Medical Committee
Editor:
Michael Kelly, D.O.

INFECTIOUS DISEASES

For purposes of Ringside Medicine, infectious diseases may be divided into two categories: commission directed pre-participation screening, and pre-fight identification of acute infectious diseases that may disqualify a fighter the night of a bout. The latter is usually apparent during the pre-fight interview and examination by the ringside physician.

Some jurisdictions still do not require mandatory communicable blood borne disease screening. Although there is a paucity of good literature concerning transmission of blood borne diseases during contact sports participation, it is better to err on the side of caution to ensure the safety of fighters, Commission staff, and ringside spectators, all of whom may be exposed to blood spatter during a bout.

Pre-Fight Screening

SYSTEMIC VIRAL INFECTIONS: Background

Hepatitis A is a self-limited disease that is usually transmitted through contaminated food, water (including ice) or direct person-to-person contact by the oral-fecal route. Most infected adults - are unaware of the timing or route of inoculation. It is important to note that among patients with known risk factors, seventy-two percent were related to international travel. Usually symptoms associated with hepatitis A infection occur between two to four weeks post inoculation. HAV IgM antibodies appear in the serum approximately 7-10 days post disease acquisition, precede the onset of symptoms, and remain elevated for up to twelve months. HAV IgG antibodies begin rising concurrent with HAV IgM, and remain elevated, conferring life-long immunity.

Fighters with active disease are not allowed to fight, both because the acutely ill athlete is compromised by his/her illness from the outset, and because of the potential for transmission to an otherwise healthy opponent.

Hepatitis B is a global health problem. There are an estimated 350 million carriers worldwide, with 500,000 deaths attributed to this disease annually. Chronic HBV infection is endemic in most areas of sub-Saharan Africa, Southeast Asia, China and Alaska, with an estimated carrier rate between 8-20%. The approximate carrier rate in Japan, Central Asia, the Middle East and South America is 2-7%. The United States, Canada, New Zealand, Australia and Western Europe have the lowest carrier rates. In the United States, the lower carrier rates may be partially attributed to an aggressive, mandatory school vaccination program.

In highly endemic areas, most infections occur in the perinatal period or during early childhood, when the rate of progression from acute to chronic infection is close to **90%**.

Hepatitis B is transmitted by cutaneous or mucosal exposure to infectious blood or body fluids. To date, there has been one reported case of transmission of this ailment during a street fight and one reported case of transmission during a boxing match where the opponent in question had additional risk factors for disease transmission. Hepatitis B can persist for extended periods of time outside the human body (up to two weeks). Transmission through contaminated toothbrushes and razors has been reported. It is

persist for extended periods of time outside the human body (up to two weeks). Transmission through contaminated toothbrushes and razors has been reported. It is imperative that ring and cage floors be cleansed thoroughly after a bloody bout, especially in jurisdictions where blood tests are not mandatory, particularly with the amateurs.

The following chart illustrates the clinical, virologic and serologic course of acute hepatitis B:

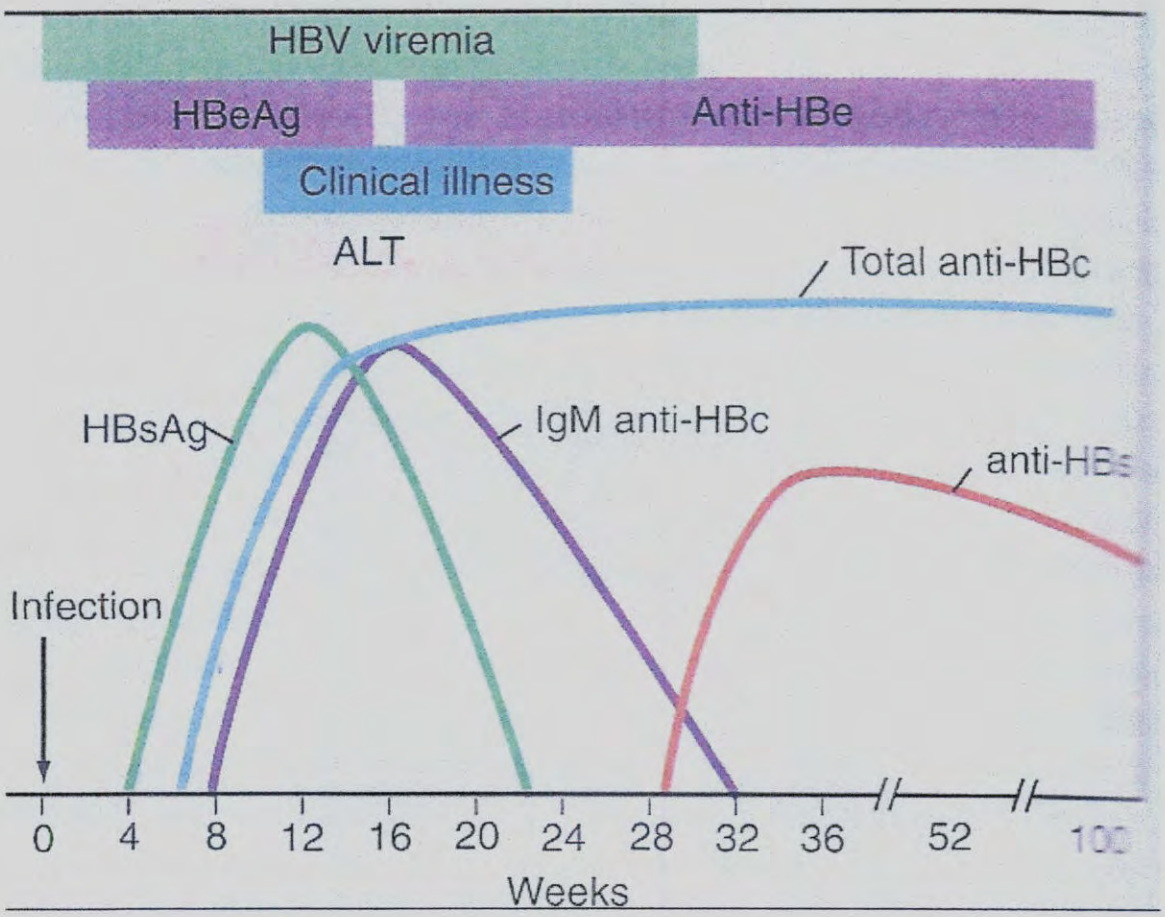

Serological markers of HBV infection

During HBV infection, the serological markers vary depending on whether the infection is acute or chronic.[11, 23, 31]

Antigens	Antibodies
HBsAg Hepatitis B surface antigen is the earliest	anti-HBs This is the specific antibody to hepatitis B

presence persists for more than 6 months. It is useful for the diagnosis of HBV infection and for screening of blood. Its specific antibody is anti-HBs.	indicates clinical recovery and subsequent immunity to HBV. Anti-HBs can neutralize HBV and provide protection against HBV infection.
HBcAg Hepatitis B core antigen is derived from the protein envelope that encloses the viral DNA, and it is not detectable in the bloodstream. When HBcAg peptides are expressed on the surface of hepatocytes, they induce an immune response that is crucial for killing infected cells. The HBcAg is a marker of the infectious viral material and it is the most accurate index of viral replication. Its specific antibody is anti-HBc.	anti-HBc This is the specific antibody to hepatitis B core antigen. Antibodies to HBc are of class IgM and IgG. They do not neutralize the virus. The presence of IgM identifies an early acute infection. In the absence of HBsAg and anti-HBs, it shows recent infection. IgG with no IgM may be present in chronic and resolved infections. Anti-HBc testing identifies all previously infected persons, including HBV carriers, but does not differentiate carriers and non-carriers.
HBeAg Hepatitis B e antigen appearing during weeks 3 to 6 indicates an acute active infection at its most infectious period, and means that the patient is infectious. Persistence of this virological marker beyond 10 weeks shows progression to chronic infection and infectiousness. Continuous presence of anti-HBe indicates chronic or chronic active liver disease. HBeAg is not incorporated into virions, but is instead secreted into the serum. Mutant strains of HBV exist that replicate without producing HBeAg. HBeAg's function is uncertain. Its specific antibody is anti-HBe.	anti-HBe This is the specific antibody to hepatitis B e antigen. During the acute stage of infection the seroconversion from e antigen to e antibody is prognostic for resolution of infection. Its presence in the patient's blood along with anti-HBc and in the absence of HBsAg, anti-HBs and core HBV mutants indicates low contagiousness and convalescence. [31]

HBxAg Hepatitis B x antigen is detected in HBeAg positive blood in patients with both acute and chronic hepatitis. HBxAg is a transcriptional activator. It does not bind to DNA. Its specific antibody is anti-HBx.	anti-HBx This is the specific antibody to hepatitis B x antigen. It appears when other virological markers are becoming undetectable.
HBV DNA HBV DNA is detectable by hybridization assays or PCR as soon as 1 week after initial infection. The tests are generally performed for monitoring of antiviral treatment or to detect mutants that escape detection by current methods.	
HBV DNA polymerase Tests for the presence of HBV DNA polymerase, detectable within 1 week of initial infection, are only performed for research purposes.	

HBV serological markers in hepatitis patients

The three standard blood tests for hepatitis B can determine if a person is currently infected with HBV, has recovered, is a chronic carrier, or is susceptible to HBV infection.[15, 23, 31]

Assay results			
HBsAg	anti-HBs	anti-HBc	Interpretation
+	-	-	Early acute HBV infection

+	+/-	+	Acute or chronic HBV infection. Differentiate with IgM-anti-HBc . Determine level of infectivity with HBeAg or HBV DNA.
-	+	+	Indicates previous HBV infection and immunity to hepatitis B.
-	-	+	Possibilities include: past HBV infection; low-level HBV carrier; time span between disappearance of HBsAg and appearance of anti-HBs; or false-positive or nonspecific reaction. Investigate with IgM anti-HBc, and/or challenge with HBsAg vaccine. When present, anti-HBe helps validate the anti-HBc reactivity.
-	-	-	Another infectious agent, toxic injury to the liver, disorder of immunity, hereditary disease of the liver, or disease of the biliary tract.
-	+	-	vaccine-type response.

From: Hollinger FB, Liang TJ. Hepatitis B Virus. In: Knipe DM et al., eds. Fields Virology, 4th ed., Philadelphia, Lippincott Williams &Wilkins, 2001:2971-3036,[15] with permission (http://lww.com).

Interpretation of HBV serologic markers in patients with hepatitis.[15]

Serological test findings at different stages of HBV infection and in convalescence

			anti-HBc			
Stage of infection	HBsAg	anti-HBs	IgG	IgM	HBeAg	anti-HBe

late incubation period	+	-	-	-	+ or -	-
acute hepatitis B or persistent carrier state	+	-	+	+	+	-
HBsAg-negative acute hepatitis B infection	-	-	-	+	-	-
recovery with loss of detectable anti-HBs	-	-	+	-	-	-
healthy HBsAg carrier	+	-	+++	+ or -	-	+
chronic hepatitis B, persistent carrier state	+	-	+++	+ or -	+	-
HBV infection in recent past, convalescence	-	++	++	+ or -	-	+
HBV infection in distant past, recovery	-	+ or -	+ or -	-	-	-

recent HBV vaccination, repeated exposure to antigen without infection, or recovery from infection with loss of detectable anti-HBc	-	++	-	-	-	-

From: Robinson WS. Hepatitis B virus and hepatitis D virus. In: Mandell GL, Bennett JE, Dolin R, eds. Principles and Practice of Infectious Diseases, 4th ed. New York, Churchill Livingstone, 1995:1406-1439,[31] with permission.

Hepatitis B virus serological markers in different stages of infection and convalescence.[23, 31, 52]

Serological and clinical patterns of acute or chronic HBV infections

Acute HBV infection

From: Mahoney FJ, Kane M. Hepatitis B vaccine. In: Plotkin SA, Orenstein WA, eds. Vaccines, 3rd ed. Philadelphia, W.B. Saunders Company, 1999:158-182,[15] with permission .

Titre of hepatitis B surface antigen (HBsAg), antibody to hepatitis B core antigen (anti-HBc), IgM anti-HBc, and antibody to hepatitis B surface antigen (anti-HBs) in patients with acute hepatitis B with recovery.[23]

Chronic HBV infection

From: Mahoney FJ, Kane M. Hepatitis B vaccine. In: Plotkin SA, Orenstein WA, eds. Vaccines, 3rd ed. Philadelphia, W.B. Saunders Company, 1999:158-182,[15] with permission.

Titre of hepatitis B surface antigen (HBsAg), antibody to hepatitis B core antigen (anti-HBc), and IgM anti-HBc during progression to chronic hepatitis B virus infection.[23]

Discordant or unusual hepatitis B serological profiles requiring further evaluation

Repeat testing of the same sample or possibly of an additional sample is advisable when tests yield discordant or unusual results.[15]

HBsAg positive /	An HBsAg-positive response is accompanied by an

anti-HBc negative	anti-HBc negative reaction only during the incubation period of acute hepatitis B, before the onset of clinical symptoms and liver abnormalities.
HBsAg positive / anti-HBs positive / anti-HBc positive	Uncommon, may occur during resolution of acute hepatitis B, in chronic carriers who have serious liver disease, or in carriers exposed to heterologous subtypes of HBsAg.
anti-HBc positive only	Past infection not resolved completely
HBeAg positive / HBsAg negative	Unusual
HBeAg positive / anti-HBe positive	Unusual
anti-HBs positive only in a nonimmunized person	It may be a result of passive transfer of anti-HBs after transfusion of blood from a vaccinated donor, in patients receiving clotting factors, after IG administration, or in newborn children of mothers with recent or past HBV infection. Passively acquired antibodies disappear gradually over 3 to 6 months, whereas actively produced antibodies are stable over many years. Apparently quite common when person has forgotten his/her immunization status

Unusual proteins from mutant HBV strains may escape diagnostic detection. The presence of different serological markers should therefore be tested for a correct

diagnosis. Diagnostic kits should contain antibodies against a variety of mutant proteins, if perfection is the goal.

Assays that detect hepatitis B viral DNA are used to determine active virus multiplication because this correlates with infection risk: the higher the titer of viral DNA, the more infectious the combatant. For patients with chronic disease, high levels of viral DNA are associated with an increased risk of liver damage.

Most Commissions require a negative hepatitisB sAg at minimum during screening. Ideally, a hepatitis BeAg, hepatitisB c Ag and Ab , hepatitis B sAg and Ab should be included in this panel. If a fighter presents with an unusual profile, or the reviewing physician is unfamiliar with nuances of hepatitis serology, referral to the ABC medical committee or to an infectious disease specialist prior to clearance is recommended.

Athletes infected with hepatitis B should be disqualified from competition. Although controversial, chronic carriers of hepatitis B with negative viral loads are presently NOT allowed to compete.

If a fighter screens positive for hepatitis B, it should be recommended that he/she also be screened for hepatitis D, since hepatitis D is dependent on hepatitis B for its successful assembly. Hepatitis D may cause minimal to no sequelae or may result in fulminant hepatitis.

Although a moot point with respect to fighter clearance, this is clearly a medical and community health issue about which the fighter need be informed.

HEPATITIS C

Hepatitis C is the leading cause for liver transplantation in the United States. An estimated 170 million people worldwide are infected with this virus. The disease is most frequently contracted through intravenous drug abuse, but a recent CDC report stated that as many as 32% of those with newly diagnosed disease had no apparent risk factor(s). The absence of symptoms associated with acute infection (approximately 75-85% of cases) and the high propensity for chronic disease (85%) make it imperative that all fighters, whether amateur or professional, be screened for this agent.

HCV RNA becomes detectable in the serum within one to eight weeks after exposure. However, blood titers of viral RNA fluctuate, and some patients may have undetectable levels of HCV RNA (be intermittently negative) at the time they are tested.
THE MINIMUM INTERVAL required to effectively exclude infection after a suspected exposure HAS **NOT** BEEN DEFINITIVELY ESTABLISHED.

Tests for antibodies against the virus (anti-HCV), usually performed by the ELISA (Enzyme Linked Immunosorbent Assay) method, become positive as early as eight weeks post infection. A positive ELISA does NOT distinguish between a cleared infection and a chronic infection.
At present, a competitor who presents with a negative HCV RNA and a positive anti-HCV should be restricted from participation in combat sports.

HIV

Infection with Human Immunodeficiency Virus (HIV) causes progressive destruction of the host immune system. HIV has been responsible for more than 22 million deaths since the 1980s. At present, there is no cure and no vaccine.

Transmission of the virus occurs through cutaneous, mucus membrane or percutaneous routes. Data compiled from health care workers exposed to the virus by a single needle stick showed a seroconversion rate of 0.3%; the seroconversion rate after mucus membrane or cutaneous exposure has been reported as 0.09%. Although there is a paucity of literature regarding transmission of HIV through exposure during combat sports participation, it can be inferred that the quantity of blood-contaminated body fluid to which a health care worker may be exposed is likely much smaller than that of a combat sports athlete, and therefore, the possibility of contracting infection may be increased by participation. There are a number of factors that contribute to increased risk. These include abrasions from gloves, grappling when one or both competitors are bleeding, and direct blood exposure from a lacerated competitor in the superior grappling position into the eyes or mucus membranes of his/her opponent in the bottom position. A poorly controlled laceration may further increase this risk because of prolonged exposure throughout the bout.

For the purpose of public health, competitor safety, commission staff safety and even audience safety, it is the current recommendation of the ABC medical committee that all fighters, whether amateur or professional, be screened for HIV (both 1/2).

HIV SCREENING

After infection with HIV, intense viral replication results in high plasma levels of HIV RNA

and HIV p24.protein. Anti-viral antibody production occurs at a later time, which results in a variable period where the infection is present but undetectable with current assays.

Serologic tests for HIV are broadly divided into two categories, screening tests, which are highly sensitive, and confirmatory tests, which are highly specific.
In the United States, the FDA has approved the qualitative HIV RNA detection assay for both screening and confirmation, but not both in a single individual. ELISA or p24 antigen assays are used for initial testing. The results are reported as reactive or non-reactive.

Western Blot or immunofluorescence assays have been approved by the FDA in the U.S. as confirmatory tests. The results are reported as positive, negative or indeterminate.

EPSTEIN BAR VIRUS (EBV) AND CYTOMEGALOVIRUS (CMV)

EBV and CMV can cause the syndrome known as infectious mononucleosis. The symptoms of acute infection include fever, sore throat, and lymphadenopathy. Hepatomegaly is present in 10-15% of cases. Splenomegaly may occur in approximately 50% of cases. The first two to three weeks of illness have the greatest risk of organ rupture.

If a fighter declares a history of mononucleosis within six months of his/her pre-participation physical examination, an abdominal ultrasound is indicated to exclude organomegaly prior to clearance. In the absence of prior Commission reviewed pre-participation medical requirements, the clearing physician at the event must perform an extensive abdominal examination to rule out hepatosplenomegaly. If there is any concern at all, the fighter should be restricted from competition, and suspended until the results of a normal abdominal ultrasound are submitted to the Commission.

Fighters with acute mononucleosis should be restricted from competition because they have an increased risk of splenic and liver rupture.

INFECTIOUS DISEASE CONSIDERATIONS FOR THE PRE-FIGHT EXAMINATION

The pre-fight history should include questions pertaining to whether the fighter has had a fever, or a recent upper or lower respiratory infection, or housemates who have been recently ill. If the athlete appears congested, but has no signs of lower respiratory illness on physical examination, he/she may be cleared for competition providing the competitor can keep his/her mouthpiece in place when asked to do 20 jump squats.

A fighter who has partially completed a course of antibiotics for bronchitis or a "mild case of pneumonia" should be evaluated on a case-by case basis. Treatment with oxiquinolones is a relative contraindication to competition, as they have been reported to increase the risk of tendon tears. If the fighter has fever, a relative tachycardia (remember, a heart rate of 80 or 90 may not be normal for a well conditioned athlete), or is dehydrated, he/she should be disqualified. A fighter may be considered for competition if he/she is asymptomatic fight night.

TUBERCULOSIS

Tuberculosis is prevalent in certain areas of the world. In the United States, antibiotic resistant variants have become more prevalent. The physician's primary care physician should be responsible for screening for this ailment.

Mycobacteria are spread in fomites. It is believed that prolonged periods of contact are required for person-to person transmission. It is therefore unlikely that this ailment would be transferred to a competitor during competition.

References:

1. NIH website: www.**nih**.gov
2. Mandell, Douglas and Bennett. *Principles of Infectious Diseases, seventh edition.* pages1577-1592, 1647-1648, 1652-1654, 1679.

Neurologic Issues in Ringside Medicine

Contributors:
Anthony L. Petraglia, M.D.
Julian E. Bailes, M.D., Chair, Department of Neurosurgery, WVU

Editors:
Michael Kelly, D.O.
Sheryl Wulkan, M.D.

NEUROLOGIC ISSUES IN RINGSIDE MEDICINE

It is important for medical personnel involved with combat sports to understand the different types of head trauma that may ensue from participation in these activities. Similarly, it is paramount for the healthcare provider to know the signs and symptoms of head injuries that require emergent care. The ability to recognize, assess, triage, stabilize and transport a fighter within minutes of his/her sustaining injury, is an essential skill required by all ringside physicians. Remember, the most dramatic, audience pleasing knock-outs are not necessarily the ones causing the most trauma; while it is easy to develop "spectator syndrome", we must always remain objective in our ringside observations.

Biomechanics/Pathophysiology

The potential for acute neurologic injury is related to the manner in which a combat athlete's strike is delivered to his opponent, as well as to how the mechanical forces are transferred and absorbed through the intracranial cavity. Studies looking at the biomechanics of collision forces have shown that rotational forces, like those that may occur with a hook or a roundhouse kick, tend to deliver more energy than linear strikes. Additionally, the force transmitted by a punch is directly proportional to the blow's velocity and the mass of the glove. According to **Sports Science,** the forces produced by kicking can be vastly greater than those produced by punches. Shogun Rua's roundhouse kick generated 2749 pounds of force (approximately the equivalent of 39 mph). By comparison, his linear punch generated 1169 pounds of force at the point of impact (approximately 25 mph). Impacts may produce rotational (angular) and/ or linear (translational) acceleration. Rotational injury occurs when a strike causes a rotational movement of the skull that can potentially stretch or tear cerebral blood vessels and shear brain tissue. This type of injury more frequently occurs with hooks, upper cuts, over hand punches, and Thai or round house kicks. Direct facial blows can cause linear acceleration resulting in skull (and subsequently, brain) movement in an anterior- to - posterior direction. This type of injury is more frequently associated with blows delivered from jabs, crosses, front kicks or sidekicks. Because the brain is bathed in cerebrospinal fluid, its motion is slower than that of the skull, and therefore the impact of the brain within the hard calavarium may result in coups and contre-coups injuries. (an analogy may be made to rocking a soft-boiled egg back and forth). Brain impact deceleration injury can occur when a combatant falls from a strike, or is thrown by his opponent, in a manner that limits his/her ability to soften the impact with correct falling techniques.

Concussion

Concussions are by far the most common type of sports-related head injury and are the most common acute neurologic issue in boxing, mixed martial arts and kickboxing. A concussion can be defined as a complex pathophysiologic process affecting the brain, induced by traumatic biomechanical forces. Simply put, it is a temporary disruption of brain function that typically resolves spontaneously. Current research suggests that concussions involve a complex cascade of trauma-induced metabolic events that result in an alteration of glucose metabolism. The etiology behind the cascade seems to be a

transient, mechanically induced change in neuronal ion permeability affecting sodium, potassium and calcium channels.

Concussions can be caused either by a direct blow to the head, face or neck, or a blow elsewhere on the body with an "impulsive" force transmitted to the head. While concussion does result in neuropathological changes at the ultra-structural level, the acute clinical symptoms largely are a reflection of a functional disturbance, and typically there is no abnormality on standard imaging studies. However, more recent advances in diagnostic imaging studies, such as computerized neuropsychiatric testing, functional MRI and positron emission tomography (PET), may reveal subtle brain injury.

While a knockout is synonymous with concussion, the majority of concussions acquired during combat sports events are not associated with a loss of consciousness, but are more commonly associated with transient cognitive impairment and /or loss of motor tone. Cognitive impairment after a match may include problems with attention, planning, memory and emotional lability. Participants may experience a persistent post-concussive syndrome that could include physical symptoms such as headaches, dizziness, photo-/phonophobia or insomnia. Some may even experience behavioral symptoms such as anxiety, depression or irritability. Alterations in cognitive function and memory are more predictive of concussion severity. Concussions that resolve within 7-10 days usually have no long-term sequelae.

Knockouts

There are a number of different hypothesized mechanisms for the loss of motor control or unconsciousness associated with a knockout. It has been suggested that the loss of tone/ consciousness associated with blows to the chin is caused by transmission of force through the jaw to the brainstem. A fighter who is receives a blow just behind the ear or by the angle of the jaw may undergo a sudden loss of consciousness due to one of four mechanisms: stretching of the carotid sinus, stimulation of the carotid nerve, twisting of the brainstem, or diffuse axonal injury.

Stimulation of the carotid sinus, the vagus, the trigeminal nerve or exposed parts of the liver, a punch to the eye socket (oculo-cardiac reflex), or blows to the ribs (intercostal nerves) can all result in a neurovascular knockout. These types of knockouts are characterized by a SLIGHT DELAY between the strike and loss of consciousness and/or motor tone: it takes time for the body to accommodate the reflex drop in heart rate, dilation of peripheral blood vessels, and cerebrovascular constriction that ultimately results in diminished cerebral blood flow loss of tone and loss of consciousness.

Competitors may experience a momentary loss of consciousness and motor control after a strike has been delivered to the head or body; recovery occurs quickly and there are no apparent signs of brain injury or concussion. This is known as a flash knockout. The mechanism of injury is poorly understood; it has been hypothesized that transient interruption of the vestibular and proprioceptive centers cause this phenomenon.

Brain Contusion/Parenchymal Hemorrhage

Brain contusions and intra-parenchymal hemorrhages respresent regions of primary neuronal and vascular injury. The affected regions are usually edematous with areas of punctate hemorrhages that can extend deep into the white matter or even the subdural and subarachnoid spaces. Contusions commonly occur in coup or contre-coup fashion. In coup injuries, the brain is injured directly under the area of impact, while in contre-coup injuries it is injured on the side opposite the impact as the brain glides and strikes the skull surface. After impact the brain may also become contused if it collides with bony protuberances on the inside surface of the skull. The frontal and temporal lobes are particularly susceptible to this type of injury; however, contusions can also be observed in the midbrain and cerebellum as well. The important aspect to remember about these types of brain injuries is that they can demonstrate progression over time, with respect to size and number of contusions. This progression typically occurs over the first 24-48 hours, with a proportion of cases demonstrating delayed hemorrhage occurring in areas that were previously free of blood on imaging.

Traumatic Subarachnoid Hemorrhage

Another acute neurologic injury that can be sustained by combat sports participants is traumatic subarachnoid hemorrhage (SAH). As its name implies, traumatic SAH is bleeding into the fluid-filled space around the brain called the subarachnoid space. A large percentage of serious traumatic brain injuries involve some component of this type of bleeding. While the hemorrhage can cause meningeal irritation, the condition is usually not life threatening and no immediate treatment is required for a good outcome. Larger amounts of SAH may lead to vasospasm, although this is more typically observed with spontaneous aneurismal SAH. Communicating hydrocephalus can occur in a delayed fashion as a result of SAH and may clinically present with late clinical deterioration.

Acute Subdural Hematoma

Subdural hematomas (SDH) are the most common form of serious and lethal combat sports brain injuries. This type of acute neurologic injury has been most commonly associated with repetitive blows to the head, rather than a single major punch. These hemorrhages can occur at any location in the brain and typically result from a tearing of the bridging veins secondary to rotational acceleration. Subdural hematomas in younger athletes do not behave in the same manner as those usually seen in the elderly population. The younger athlete does not possess a large potential subdural space like elderly people do. As a result, mass effect, increases in intracranial pressure and clinical deterioration occur much more rapidly. Brain injury can be further compounded by significant associated underlying contusions or edema that often accompanies SDH in the athlete. Subdural hematomas sustained while boxing can result in a wide variety of sequelae, ranging from mild symptoms such as headaches, to focal neurologic deficits and even death. Athletes may become unconscious and/or experience focal neurological deficits immediately, or symptoms may develop more insidiously over time.

The prognosis is typically less favorable than with other types of acute neurologic injuries in combat sports participants, with relatively high mortality rates. *

Epidural Hematoma

Epidural hematomas (EDH) are a common traumatic brain injury (TBI) in athletes, especially in sports where participants are not helmeted such as baseball. or rugby.Although less common than other TBI in combat sports participants, these injuries may typically occur after head to head impact. After being stunned for a brief moment, the competitor may appear to be fully alert. A short time thereafter, the athlete may experience a sudden excruciating headache followed by progressive neurological deterioration. Fewer than one third of people who sustain an EDH have the classically, clinically described "lucid interval". Therefore, it is essential to recognize this injury early on in order to commence appropriate management. If treated early, complete neurologic recovery can typically be expected, as EDH are usually not associated with other underlying brain injuries.

Diffuse Axonal Injury

Diffuse axonal injury (DAI) is a less localized but more severe type of acute neurologic Injury that can occur in combat sports. It is the result of shearing of multiple axons secondary to rotational forces (acceleration) on the brain, usually from lateral rotation of the head. Parts of the brain such as the cortex (grey matter) and white atter have various densities and different physical properties that will accelerate at different speeds upon impact, resulting in shearing. Additionally, the rotational acceleration of the head results in a swirling motion of the brain around pedicles of blood vessels. As a consequence, such an injury results in punctate hemorrhages from small vessel tears, in addition to the diffuse tearing of white matter fiber tracts.

Carotid/Vertebral Artery Dissections

Punches to the head that cause that cause sudden flexion or extremely rapid rotation of the neck can tear the intima of the carotid or vertebral arteries. Injuries to these vessels must not be overlooked as potential acute neurologic injuries. Such tears or dissections can extend near the skull base resulting in vessel occlusion and possible cerebral ischemia or infarction.

Second-Impact Syndrome

Second-impact syndrome is defined a a fatal, malignant and uncontrollable increase in intracranial pressure caused by diffuse cerebral edema that occurs after an impact to the head is sustained prior to complete recovery from a previous head trauma. Significant controversy exists about the validity of this condition and its precise frequency in sports is unknown; however, numerous cases have been reported in the literature and most involve adolescent males or young adults. An athlete who participates in a contact sport while being symptomatic from a prior concussion appears to be at increased risk. The second-impact syndrome may be more likely to occur in a tournament setting where an athlete competes more than once in a short time period. The pathophysiologic

mechanism is thought to involve a dysfunction of cerebral autoregulation leading to vascular engorgement and diffuse cerebral edema, which in turn markedly increases intracranial pressure and can lead to brain herniation syndromes. This neurologic deterioration after the second impact occurs rapidly within seconds to minutes. Second-impact syndrome is associated with a high mortality rate and nearly 100% morbidity rate. It is an important acute neurologic injury to keep in mind when making return-to-play decisions about an athlete who has suffered a TBI.

Risks for Sustaining Acute Neurologic Injuries

The literature contains studies reporting conflicting results regarding age, gender, experience and various measures of exposures as risk factors for acute neurologicall Injuries in combat sports. Several groups of boxers though, have a theoretically higher risk of sustaining neurologic injuries-including those that are fatigued or dehydrated. A large number of brain injuries sustained by combat sports participants occur as a result of fatigue. As participants fatigue, they tend to rely more on instinct and as a result, become increasingly oblivious to the amount of trauma they are receiving. There is a decreased ability to maintain good balance and block or avoid punches as the fighter becomes progressively fatigued. Since his/her reaction time is negatively affected, the fighter also becomes less able to avoid a strike. This loss of defensive ability makes the fatigued combat sports athlete more vulnerable to neurologic injuries.

Dehydration can occur as a result of weight cutting prior to a weigh-in, or as a result of perspiration during a match, and can increase a participant's vulnerability to acute neurologic injury. Dehydration can contribute to, and can accentuate fatigue, thereby affecting an athlete's ability to defend him/herself. Additionally, dehydration can decrease the amount of cerebrospinal fluid (CSF) surrounding the brain, which normally provides a buffer for the brain from trauma.. Furthermore, a decrease in CSF may enlarge the potential space around the brain, increasing the likelihood of developing hemorrhages such as subdural hematomas.

Combat Sports Fatalities*

There is a paucity of validated epidemiological data on this subject. To date, there have been three deaths attributable to mixed martial arts events, all due to head injuries. From what can be gleaned from the literature, it appears that the rate of boxing fatalities has declined over the past few decades. The decline in fatalities may be partially attributable to rule changes including the implementation of fewer rounds per fight, as well as medical advances that have improved both the diagnosis and treatment of the acutely injured fighter. The majority of boxing fatalities are due to subdural hematomas: typically, these are associated with an immediate loss of consciousness during the bout. While death as a result of participation in combats sports have received plenty of media attention, a literature search suggests that the fatality rate in boxing actually compares favorably to many other sports that receive less attention with respect to participant safety, such as horse-racing, sky diving, hang gliding and mountaineering.

- Most of this information is based on boxers as a subset of combat sports participants. To date, there have been three reported deaths in mixed martial arts

competition, all in jurisdictions that do not require CT or MRI/MRA as part of a pre-participation evaluation. One of the deaths was believed to be due to a ruptured aneurysm, one was attributed to second impact syndrome, and the third was attributed to a subdural hematoma. Other than the first case mentioned, the editor has been unable to verify these statements.

Suggested Reading/References

Cantu RC, Voy R: Second impact syndrome: a risk in any contact sport. *Phys Sportsmed* 14(10):75-83, 1986.

Cantu RC: *Boxing and medicine.* Champaign: Human Kinetics; 1995.

Gambrell RC: Boxing: medical care in and out of the ring. *Current Sportsmed Reports* 6:317-321, 2007.

Guterman A, Smith RW: Neurological sequelae of boxing. *Sports Med* 4:194-210, 1987.

Jordan BD, Campbell E: Acute boxing injuries among professional boxers in New York State: a two-year survey. *Phys Sportsmed* 28(2):25-26, 1998.

McCrory P, Meeuwisse W, Johnston K, Dvorak J, Aubry M, Molloy M, Cantu R: Consensus statement on concussion in sport: the 3rd international conference on concussion in sport held in Zurich, November 2008. *Br J Sports Med* 43:i76-i84, 2009.

McCunney RJ, Russo PK: Brain injuries in boxers. *Phys Sportsmed* 12:53-67, 1984.

Miele VJ, Bailes JE, Cantu RC, Rabb CH: Subdural hematomas in boxing: the spectrum of consequences. *Neurosurg Focus* 21(4):E10, 2006.

Miele VJ, Bailes JE, Voelker JL: Boxing and the neurosurgeon. *Clin Neurosurg* 49:396-406, 2002.

Miele VJ, Norwig JA, Bailes JE: Sideline and ringside evaluation for brain and spinal injuries. *Neurosurg Focus* 21(4):E8, 2006.

Parkinson D: The biomechanics of concussion. *Clin Neurosurg* 29:131-145, 1982.

Rabadi MH, Jordan BD: The cumulative effect of repetitive concussion in sports. *Clin J Sports Med* 11:194-198, 2001.

Viano DC, Casson IR, Pellman EJ, Bir CA, Zhang L, Sherman DC, Boitano MA: Concussion in professional football: comparison with boxing head impacts – part 10. *Neurosurgery* 57(6):1154-1172, 2005.

Zazryn TR, McCrory PR, Cameron PA: Neurologic injuries in boxing and other combat sports. *Neurol Clin* 26:257-270, 2008.

Addendum: Images of Subdural Hematoma, Epidural Hematoma and Diffuse Axonal Injury

Contributors:

Patricia E. Roche, D.O.,
Diagnostic Radiology

Kathleen Finzel, M.D.
Chair, Diagnostic Neuroradiology
ProHEALTHCare Associates

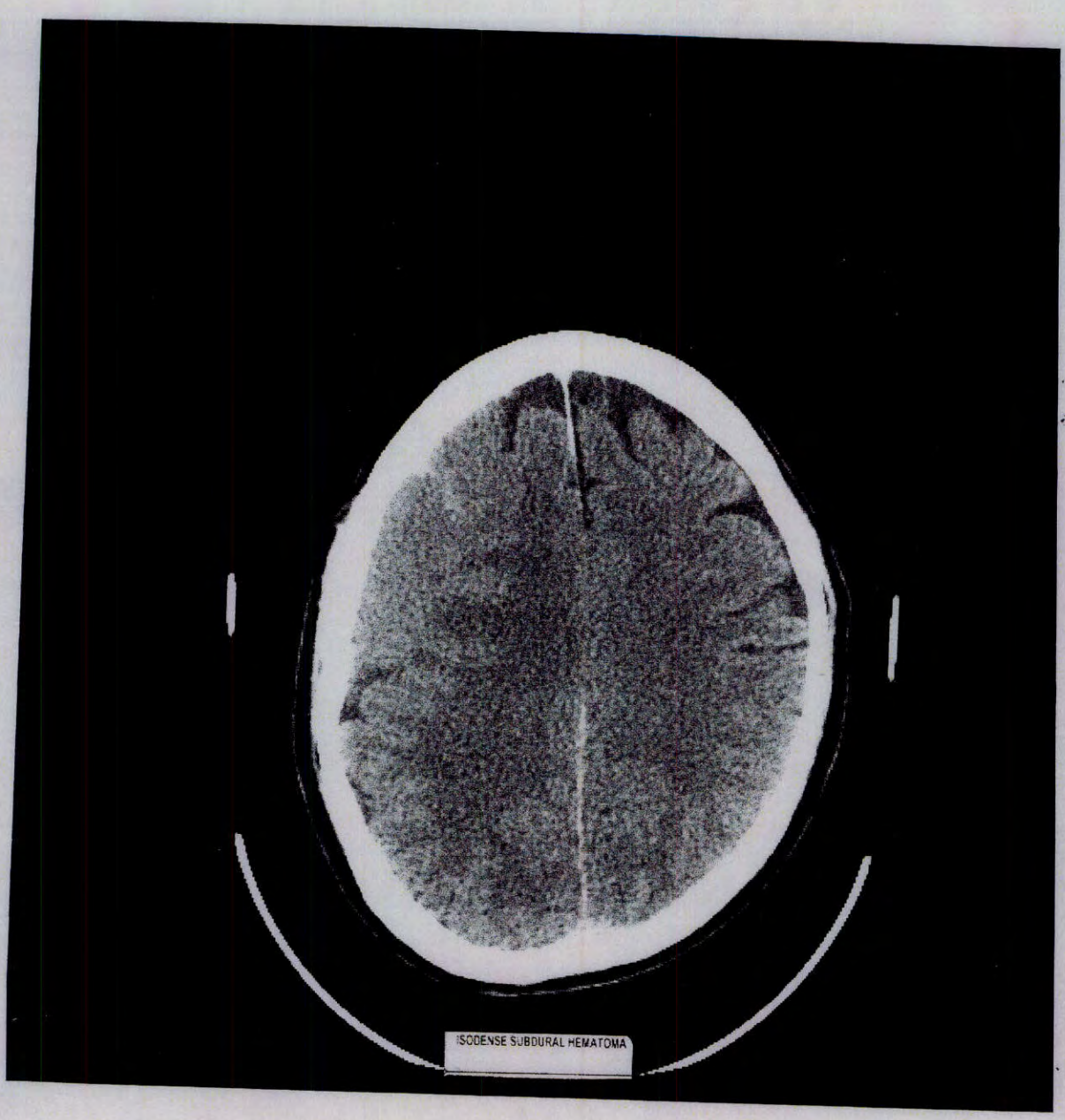
ISODENSE SUBDURAL HEMATOMA

SUBDURAL HEMATOMA

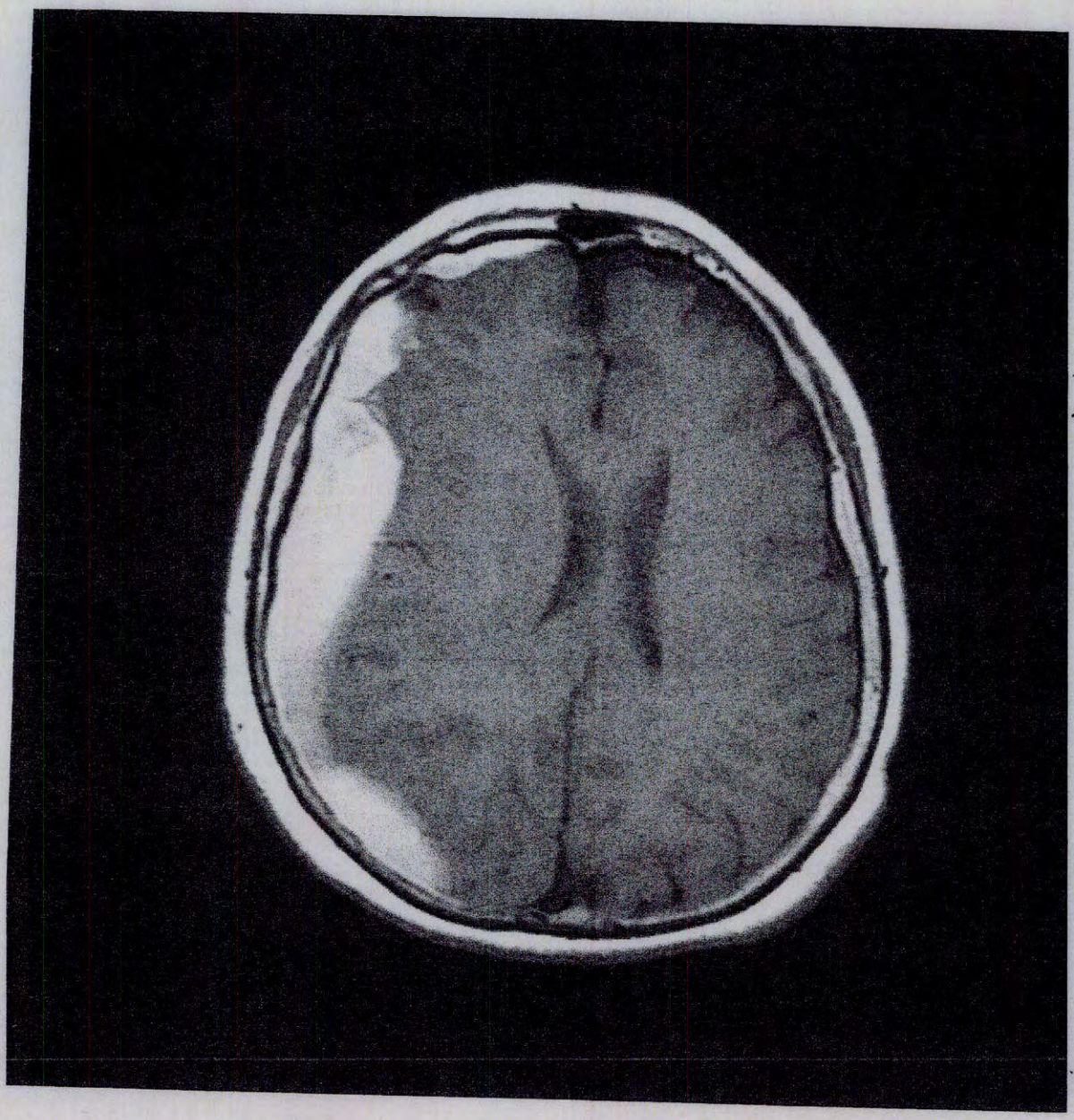

EPIDURAL HEMATOMA

DIFFUSE AXONAL INJURY
(DAI)

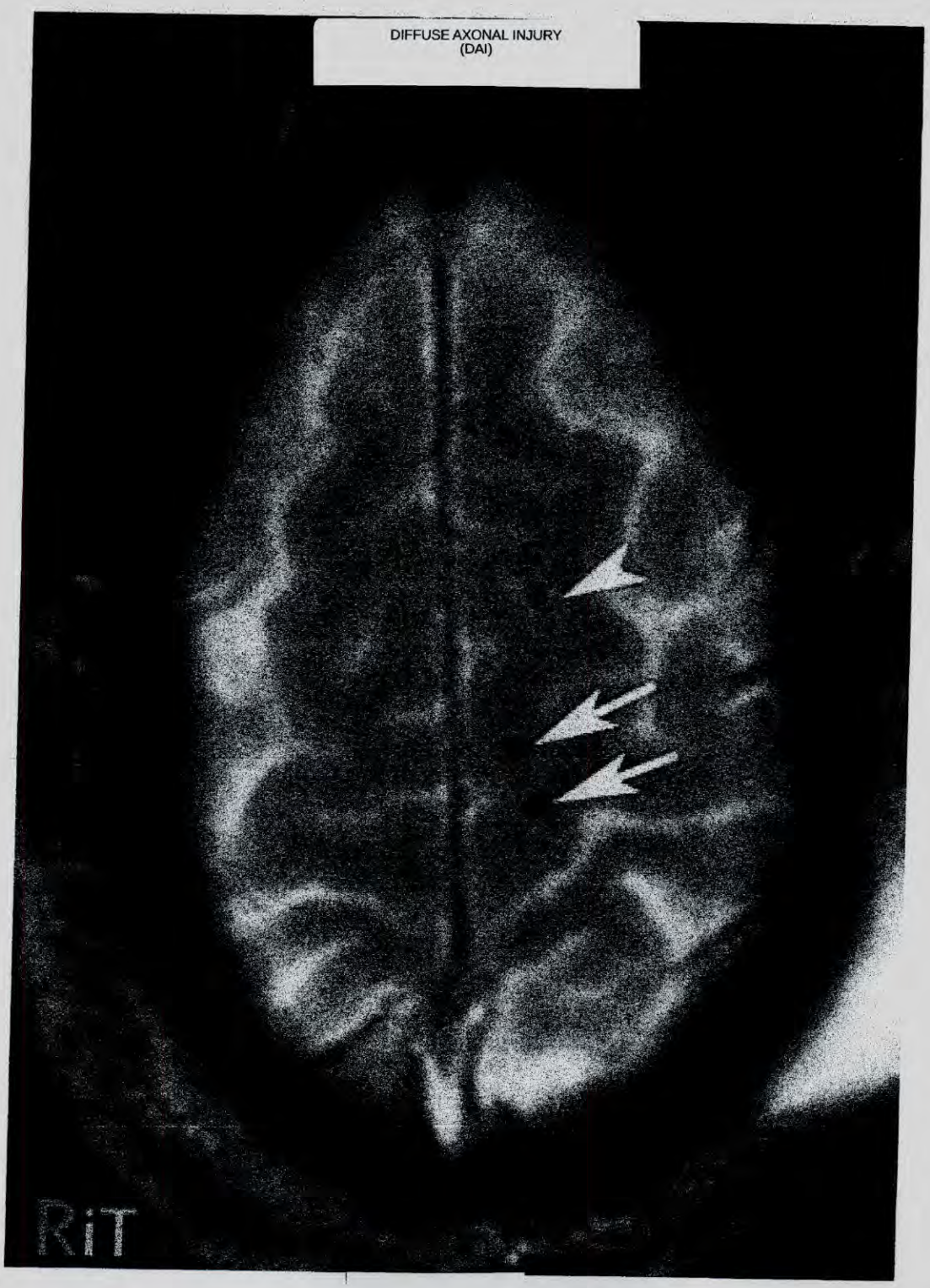



DIFFUSE AXONAL INJURY
(DAI)

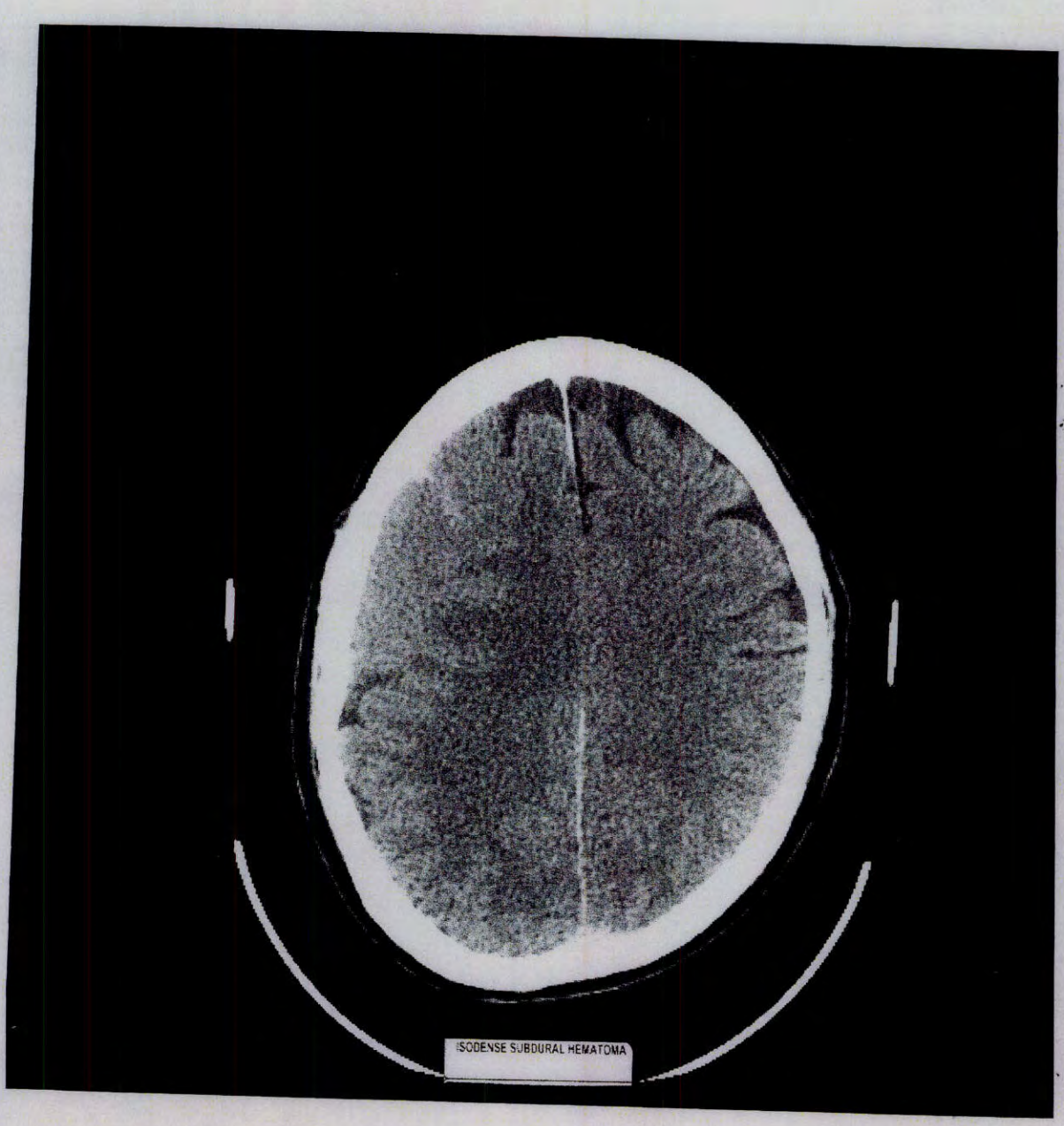
ISODENSE SUBDURAL HEMATOMA

SUBDURAL HEMATOMA



Ophthalmologic Injuries In Combat Sports

Contributors:
Anthony Curreri, M.D.
Dr. Bruce Zagelbaum, M.D.
Edited by Sheryl Wulkan, M.D.

OCULAR INJURIES

Ocular injuries occur frequently as a consequence of combat sports participation. Eye injuries range from mild and superficial, such as eyelid hematomas and corneal abrasions, to more serious injuries that require immediate recognition and attention, such as hyphema and retinal detachment. It is imperative that the ringside physician be able to recognize, evaluate and triage these injuries in a timely manner, as rapid diagnosis and treatment are essential to optimize visual outcome. A high index of suspicion for occult, visually disabling lesions is critical.

Anatomy of the Eye

Figures (1a b, c).

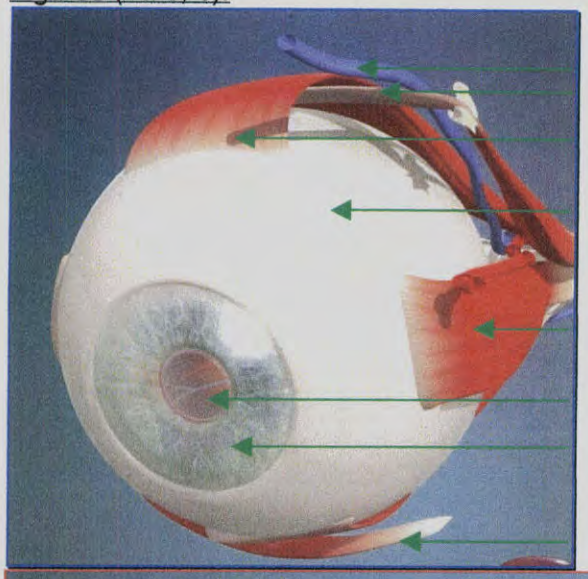

a. Superior Ophthalmic Vein
b. Superior Oblique Muscle
c. Superior Rectus Muscle

d. Sclera

e. Medial Rectus Muscle

f. Pupillary Aperture
g. Cornea

h. Inferior Oblique Muscle

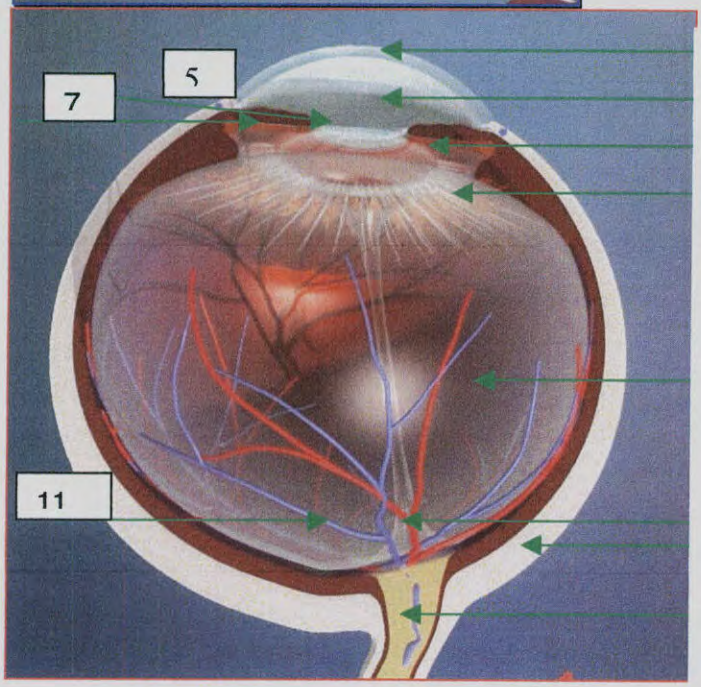

1. Cornea
2. Aqueous Humor

3. Lens
4. Suspensory Ligaments

5. Pupillary Aperture
6. Iris
7. Dilator pupillae

8. Vitreous Humor

9. Central Retinal Artery
10. Sclera
11. Central Retinal Vein
12. Optic Nerve

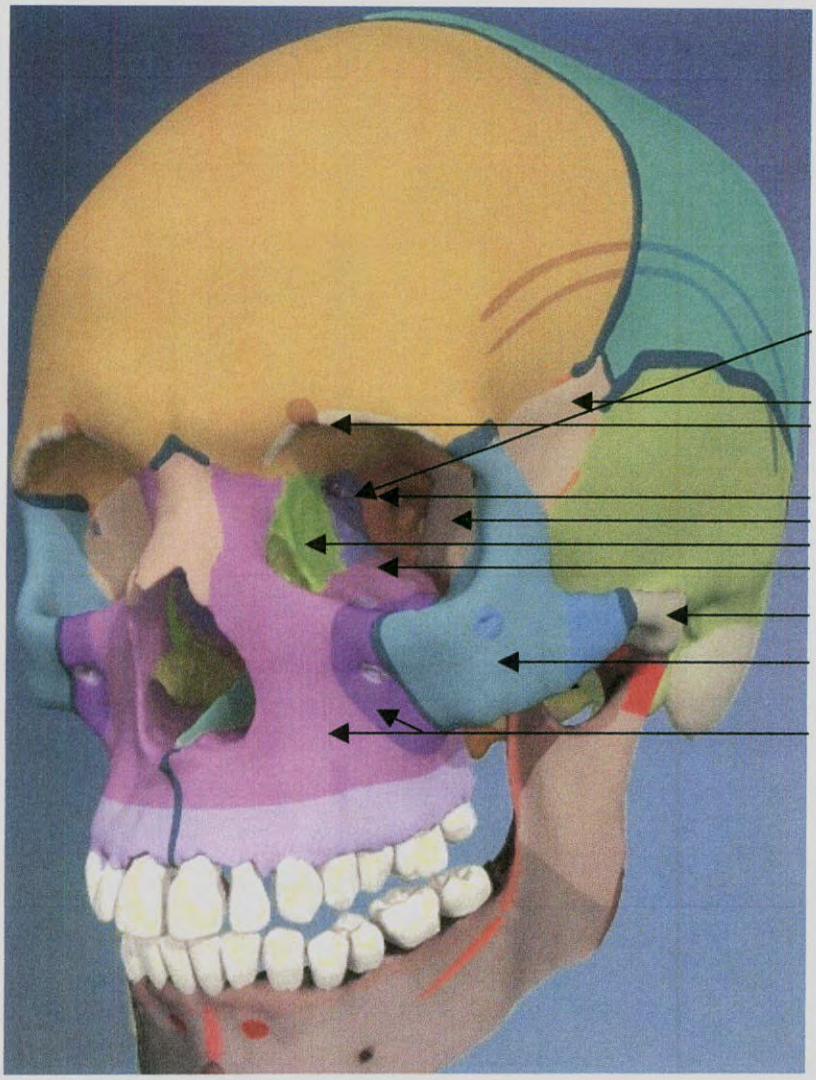

Eye Injuries In Combat Sports

External:

- Skin lacerations
- Eyelid lacerations
- Eyelid edema / hematoma
- Subcutaneous emphysema
- Ptosis
- Motility abnormality
- Pupil abnormality

Cornea:

- Abrasion

- Laceration
- Foreign Body

Conjunctiva:

- Sub-conjunctival hemorrhage

Lens:

- Traumatic cataract

Angle:

- Recession
- Synechiae

Iris:

- Sphincter tears
- Hyphema
- Iridodialysis

Macula:

- Hole
- Cyst

Retina:

- Commotio (edema)
- Hole / tear
- Detachment
- Vitreous hemorrhage
- Choroidal rupture

Orbit:

- Fracture

Physiologic Mechanisms of Injury

Three mechanisms have been described to explain the ocular complications of blunt trauma: (1) coup, (2) contrecoup, and (3) equatorial expansion.

1) **Coup:** (Figure 2)

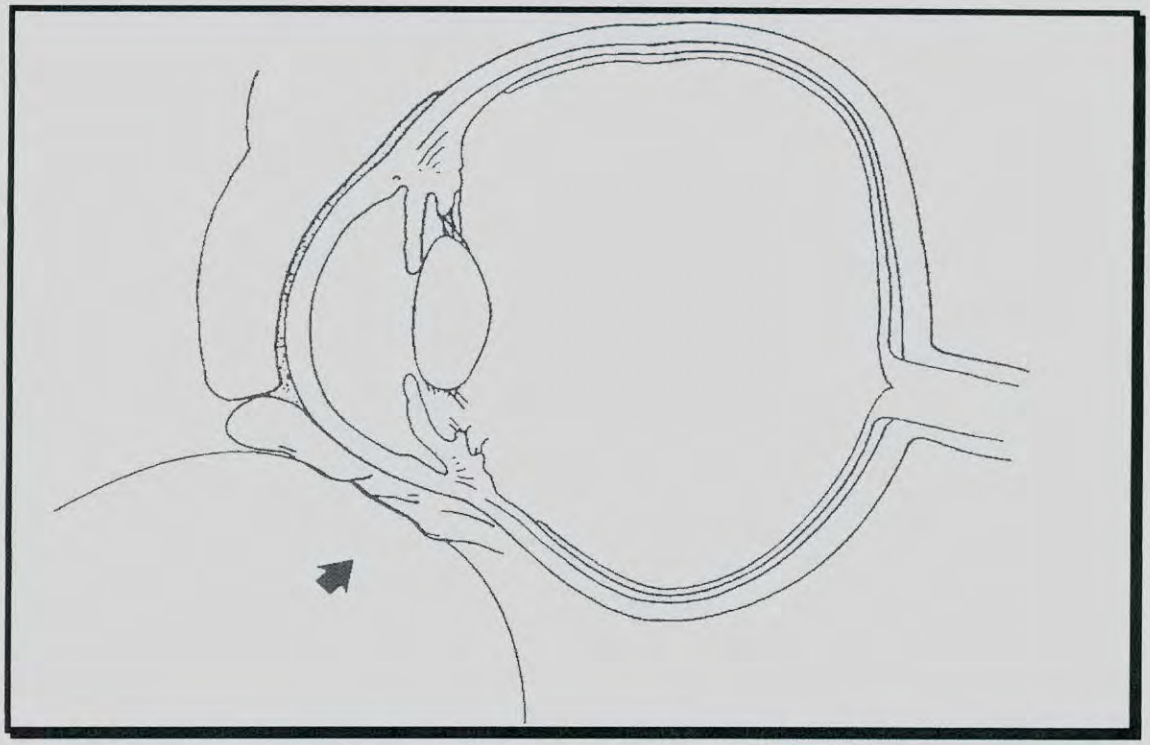

FIGURE 2 *Local damage to the eyelids occurs from a coup-type injury. Note that the direct blow to the eye (arrow) produces the local damage.*

Coup injury is caused by a direct blow that produces local damage at the point of impact. Coup forces are responsible for lacerations and bleeding of the eyelids, cornea and conjunctiva. Compressive forces on the eye from a punch or a finger can cause dramatic changes in intraocular pressure, resulting in tears to the ciliary body, and years later, possibly glaucoma. (There is also an association between hyphema and the development of glaucoma).

2) Contrecoup: (Figure 3)

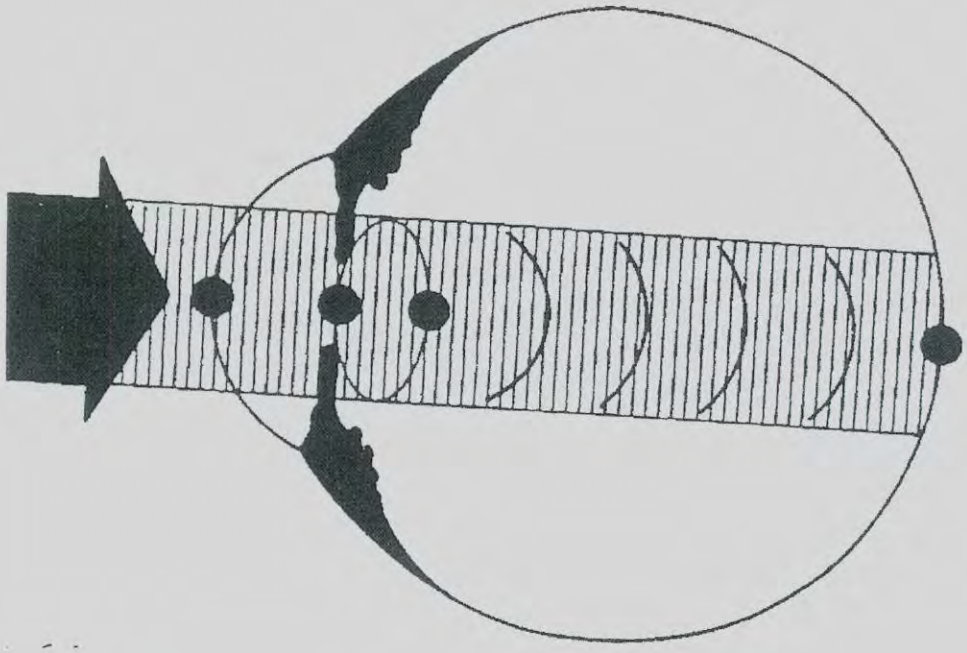

FIGURE 3 *Contrecoup lesions occur at interfaces between tissues of different densities.*

The contrecoup accounts for the damage that occurs away from the area of impact. Damage is found to be localized at interfaces or those structures that are borders between tissues of differing densities. This accounts for injuries such as cataracts, retinal edema and macular hole formation.

3) **Equatorial Expansion:** (Figure 4)

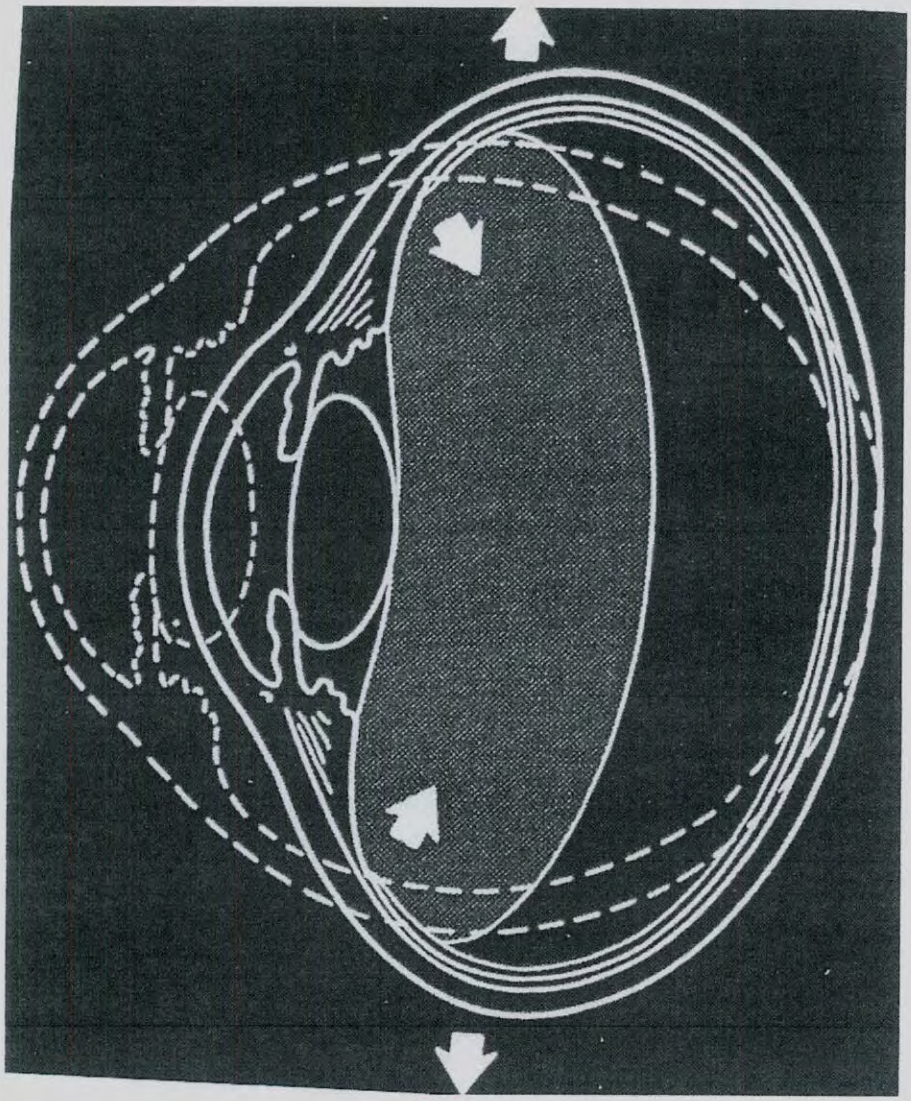

As the globe is compressed along the anterior-posterior axis, the circumference of the equator increases. As the sclera at the equator expands, the underlying retina and pars plana are suddenly pulled from their attachment to the vitreous base. This can result in an avulsion of the vitreous base, tears in the retina and retinal dialysis.

BASIC RING (CAGE) SIDE EQUIPMENT

The following items should be considered as part of a ringside physician's standard equipment:

- Reading card
- Red object (optional)
- Penlight (with cobalt blue filter)
- Fluorescein stain (strips or solution)
- Proparacaine 0.5% topical solution
- Eye Wash
- Eye patch
- Surgical tape
- Steri-strips
- Rigid eye shield (metal or plastic)
- Direct ophthalmoscope

Dermabond may also be used judiciously provided the ringside physician is familiar with the product and is aware of the potential problems caused by applying it near the eyes of a perspiring athlete. The discussion of the proper way to use Dermabond is beyond the scope of this manual.

THE RING (CAGE) SIDE EVALUATION

The ringside physician should not be distracted by impressive external injuries (like bleeding lid laceration or significant edema without underlying fracture) that have no long-term visual consequences. Otherwise he/she may overlook visually disabling injuries.
The examination of the fighter should therefore be approached systematically and methodically from a functional standpoint. In the case of the eye, this means starting from the front and external components and working methodically backward (posteriorly) toward the inside of the eye.

Neurologic Function:

This is the basis of the visual system. If there is an injury the bout should be stopped immediately.

The anatomic components of the neurologic system include:

a. The retina - is a thin wallpaper-like structure that lines the inside of the eye. It houses the photoreceptors that transform light into nerve impulses.

b. The optic nerve – is formed from the retinal ganglion cells and carries visual information to the visual cortex in the occipital lobe.

c. The pupils – receive feedback from the visual system to regulate the entrance

of light into the eye by dilating and constricting. Pupillary irregularities may be associated with a pathologic process. Using a penlight, the examiner should inspect both pupils for size, shape and reaction to light. Blunt trauma may create either a small, constricted pupil (miosis) or a large, dilated pupil (mydriasis). A dilated pupil associated with head injury may indicate increased intracranial pressure with associated neurological abnormalities. Mydriasis may also be caused by traumatic iris sphincter tears.

Direct and consensual pupillary responses to light are important to evaluate. The direct response is determined by observing the reaction of the pupil to a bright light shone directly in one eye and then the other eye while the patient is fixating on a distant target. Fixating on a near target will invoke the accommodative response, causing the pupils to constrict.

Shining a light into one eye will constrict BOTH pupils equally. The swinging light pupil test will determine the presence of a relative afferent pupillary defect (RAPD). It is important to note the defect is ***relative*** to the other eye.

The test is performed by holding a light over one eye for three seconds and then quickly moving the light source to the opposite eye. The light is swung back and forth in this manner while carefully observing the pupillary response. Classically, the affected pupil will dilate when light is shone upon it, indicating a defect in afferent optic nerve function. The presence of a RAPD is a significant finding as it may signify optic nerve trauma, and its presence should be treated as a medical emergency.
It is important to note that false negatives may occur when testing with a dim light source, a light source with a broad beam, or when the light source is held too distant from the eyes during examination.

Another quick vision test that can be performed ring (cage) side is the test for color vision. One approach to doing a fast color vision test is to assess for difference in the perception of the same red object by each eye independently. When there is optic nerve damage, the red may appear washed-out or faded in the affected eye. (Note: Approximately 6% of the male population is color blind; make sure to ask if this is the case with the competitor in question before performing this test).

External Examination

FACE AND EYELIDS

The physical examination should begin with the external examination. The eyelids and periorbital area should be inspected for abrasions, lacerations, erythema, hemorrhage, subcutaneous emphysema or any particulate matter. Any bleeding from skin wounds should be controlled with tamponade and other modalities. The skin may be cleansed with a sterile gauze sponge and sterile saline. If an eyelid laceration is present, its

location and borders should be described. Lacerations through the lid margin and involvement of the lacrimal drainage system should be noted, as they will require special surgical repair.

Subcutaneous emphysema or abnormal positioning of the globe relative to other facial structures may indicate fractures of the orbital bones or sinuses. The orbital and facial bones may be palpated for a "step-off" or area of discontinuity.

VISUAL ACUITY: Visual acuity may be assessed after the initial evaluation. A near card (Figure 5) may be used to obtain an estimate of baseline visual acuity within the ring or cage. If the examiner is not carrying a visual acuity card, he/she may ask the fighter to read the names of sponsors or T-shirt graphics. Each eye should be checked individually (not binocular testing). If unable to read, the examiner should ask the athlete to count the number of fingers held up at different distances. If unable to count fingers, a determination of hand movement or light perception vision using a penlight should be made.

EXTRAOCULAR MOVEMENTS: Abnormalities in extraocular motility may indicate the presence of orbital wall and/or floor fractures, nerve injury, injury to the muscle itself, or restriction from intraorbital edema. Motility is assessed by asking the athlete to look up, down, right and left with careful observation of any signs of restriction or paresis of movement.

ANTERIOR SEGMENT

Within the boxing ring or cage, a penlight may be used to examine the ocular surface and anterior segment. If contact lenses are worn, they should be localized. The presence of foreign bodies, lacerations, hemorrhage, edema and injection (redness) is noted. Subconjunctival hemorrhage, conjunctival edema, conjunctival/corneal lacerations, and the presence of an obvious hyphema (blood in the anterior chamber) should be noted.

The cornea is then examined with a penlight for clarity and the presence of abrasions, foreign bodies or lacerations. If the athlete is in pain, one drop of topical anesthetic (i.e., 0.5% proparacaine) may be instilled and a fluorescein strip may be dampened with a drop of sterile saline and touched to the inferior surface of the lower eyelid. Care should be taken to avoid touching the cornea directly with the fluorescein strip because this may induce a corneal abrasion. Fluorescein stain is taken up by the de-epithelialized cornea, thus indicating the presence of a corneal abrasion. The use of a penlight along with a cobalt blue filter will help identify an area with absent corneal epithelium that will appear bright green. Fluorescein may also be used to identify conjunctival abrasions.

The presence of any darkly pigmented material under the conjunctiva should be viewed with suspicion as this may represent the eye's intraocular contents protruding through a scleral perforation (ruptured globe). If a corneal laceration, hyphema or ruptured globe is considered, an eye shield (without anything underneath it) should be placed over the injured eye. Avoid any pressure on the globe.

POSTERIOR SEGMENT

Posterior segment injuries occur with higher frequency in combat sports participants due to the high incidence of blunt trauma. The "posterior segment" is the portion of the eye that is posterior to the iris. This includes the retina, optic nerve, vitreous body, and choroid. Posterior segment injuries tend to be more serious and are associated with ore severe and permanent visual loss. Suspicion of a posterior segment injury calls for referral to an ophthalmologist immediately for a dilated fundus examination. The earlier a posterior segment injury is diagnosed, the better the prognosis for maximizing visual potential. Certain questions are particularly meaningful in determining posterior segment pathology. Keep in mind that visual acuity changes may be transient or deceptively absent even in the face of an already present or impending posterior segment problem. For example, a small retinal tear may occur with little or no symptomatology after injury, yet if left untreated a retinal detachment may develop, resulting in poor vision.

The following questions should be asked:

1. Has your vision changed in any way?
2. Do you see any specks (black spots or floaters) in your vision?
3. Do you see flashing lights?
4. Do you feel that there is a veil, curtain or shade coming across your vision from any direction?

Specks (black spots) represent a change in the structure of the vitreous humor and may indicate co-existing retinal damage. The sensation of flashing lights may imply an area of vitreo-retinal traction that could lead to a retinal tear or detachment. A veil, curtain or shade coming across the vision could indicate that the retina is separating from the wall of the eye (retinal detachment).

A positive answer to any of the above questions indicates the presence of a potentially serious posterior segment injury and immediate threat to vision. This patient should have urgent evaluation by an ophthalmologist who will perform a bilateral dilated fundus examination to view the entire retina.

A bout should be stopped if the examiner finds any of the following:

1. Floaters
2. Light flashes
3. Sensation of a curtain, shade or veil coming across vision
4. Full-thickness eyelid laceration
5. Eyelid edema/hematoma causing an eye to close
6. Hyphema* (see attached photo addendum)
7. Inability to view the posterior retina using hand held ophthalmoscope
8. Onset of subcutaneous emphysema (crepitus), especially after blowing nose
9. Diminished visual acuity

Conditions that require immediate attention (should be sent to the ER or ophthalmologist on call immediately) include the following:

- Diplopia (double vision)
- Decrease in vision
- Floaters
- Flashes of light
- Eye pain

Conclusion:

Participation in combat sports can result in a wide range of eye injuries. Many of these injuries are treatable if detected early. An orderly, systematic approach to examining competitors can help in the identification and management of many ophthalmologic conditions. A low threshold for referral to an ophthalmologist is required, since many seemingly minor injuries may lead to permanent visual compromise.

FIGURE 5


95
874
2843
638 ∈ Ш ∃ XOO
8745 ∃ m Ш OXO
63925 m ∈ ∃ XOX
42836 5 Ш ∈ m oxo
37425 6 ∃ Ш ∃ xxo
93725 5 Ш m ∈ xoo
Point
Jaeger
distance equivalent
20/800
20/400
26 16 20/200
14 10 20/100
10 7 20/70
8 5 20/50
6 3 20/40
5 2 20/30
4 1 20/25
3 1+ 20/20
HAND HELD CHART
Card is held in good light 14 inches from eye. Record vision for each eye separately with and without glasses. Presbyopic patients should read thru bifocal segment. Check myopes with glasses only.

Addendum: Photographs of Some Common Ophthalmologic Injuries

Contributor:
Bruce Zagelbaum, M.D., author of "Sports Ophthalmology"

HYPHEMA

A hyphema is layering of RBCs in the inferior anterior chamber. During the slit-lamp examination, it is of the utmost importance to measure and document the height of the hyphema as this will dictate both the management and follow-up of the condition. A hyphema patient may complain of blurred near vision.

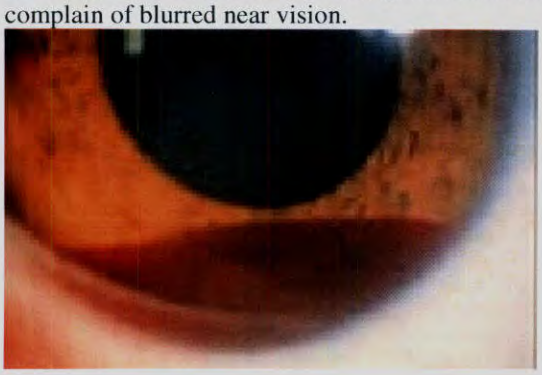

LENS SUBLUXATION

Lens subluxation is a partially dislocated crystalline lens due to incomplete zonular dehiscence secondary to equatorial expansion of the globe after trauma. A visible lens equator (sometimes with visible zonules) is the hallmark of this condition. These patients can be bothered by acquired myopia, marked astigmatism and diplopia. The symptoms can vary with head position.



GLOBE RUPTURE



A globe rupture must always be considered when evaluating a patient that has sustained blunt trauma or a lacerating injury. Some of the signs include severe subconjunctival hemorrhage, deep or shallow anterior chamber compared with the contralateral eye, hyphema, an irregularly shaped pupil peaked toward the wound, and restricted EOM (greatest in the direction of the rupture).

CORNEAL ABRASION WITH FLUORESCEIN STAIN



A corneal abrasion is the loss of the superficial epithelial layer of the cornea (a "scratch"). Fluorescein preferentially stains the abrasion site.

SUBCONJUNCTIVAL HEMORRHAGE

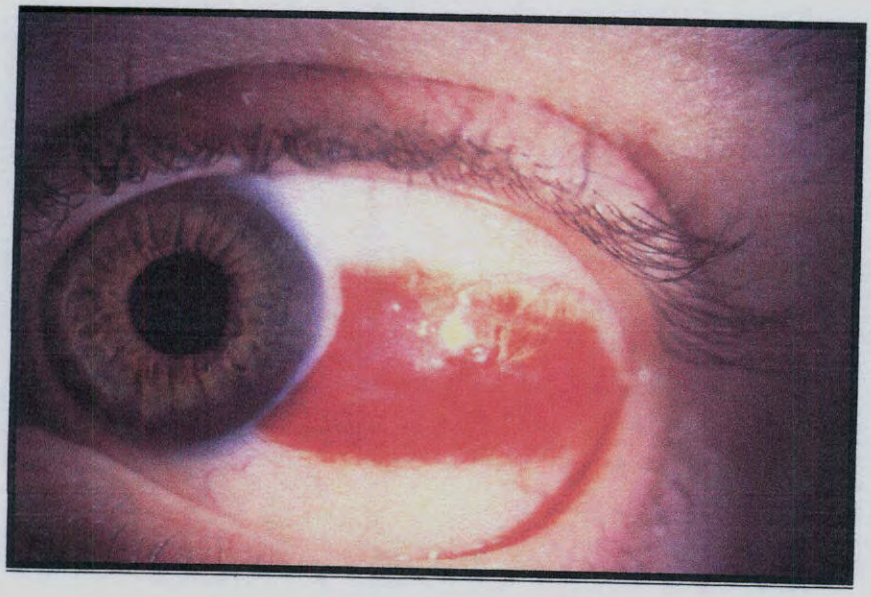

A subconjunctival hemorrhage occurs when a small blood vessel breaks just beneath the clear surface of the eye (conjunctiva). The conjunctiva can't absorb the blood very quickly, so the blood is trapped under this transparent surface. A subconjunctival hemorrhage is a harmless condition that usually resolves completely within 10 to 14 days.

FULL THICKNESS EYELID LACERATION

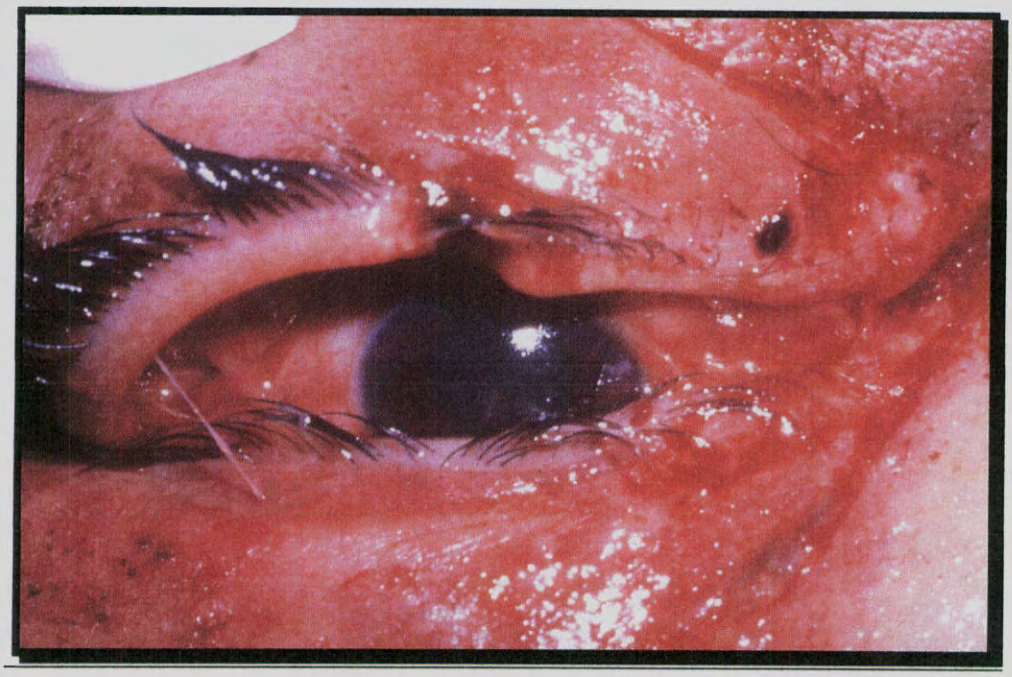

Orthopedic Injuries In Ringside Medicine

Contributor:
Michael Kelly, D.O.
Author, "Fight Medicine"
Editor:
Sheryl Wulkan, M.D.

ORTHOPEDIC INJURIES IN RINGSIDE MEDICINE

Ringside physicians must be familiar with a number of medical specialties and a vast array of injuries ranging from minor contusions to life threatening neurological assaults. Fortunately, the majority of orthopedic injuries that occur during combat sports are straight forward. The assessment, triage and emergent treatment of combat sports orthopedic injuries is facilitated by an organized approach and familiarity with common injuries.

Combat sports injury patterns generally follow the areas that are the most used and targeted. Boxers generally have upper extremity injuries involving the hands, wrists, and shoulders. Wrestlers most commonly injure the shoulder, knee or elbow. Mixed martial arts participants have the most diverse types of injuries including the shoulder, hand, elbow, knee and ankle. Additionally, mixed martial arts include joint lock submission holds that can cause instability of the involved joint due to ligament injury. For example, a kimora (type of elbow submission hold) can injure the ulnar collateral ligament of the elbow. The elbow and knee are the most commonly injured joints, but any joint can be injured with a submission hold.

Generally, the ringside assessment of combat sports injuries should include: the mechanism of injury, inspection, palpation, stability testing, strength testing and specialized diagnostic maneuvers.

The astute ringside physician will observe the mechanism of injury as it occurs during a bout. Inspection of the injured area may reveal edema and ecchymosis. However, the absence of edema and ecchymosis immediately after a bout may be misleading because both may worsen with time. Similarly, the absence of the complaint of pain immediately post fight may be misleading, since high adrenaline and endorphin levels may initially mitigate this symptom. A high index of suspicion based on clinical acumen and observation are key to making the correct diagnosis.

Palpation of an injury can lead to the correct diagnosis if the ringside physician pays careful attention to the relevant anatomy. Although displaced fractures are often evident on inspection, the presence of point tenderness and/or crepitus over bone may reveal more subtle fractures. Additionally, tenderness over soft tissues may confirm a contusion, tendon, ligament or muscle injury.

As noted previously, joint lock submission maneuvers can injure ligaments associated with the attacked area. Stability testing often helps to identify and grade ligament injuries. Ligament injuries (sprains) are graded I to III. Grade I ligament injuries involve microscopic tears with no change in ligament length and no laxity on examination. Grade II ligament injuries involve macroscopic teas and changes in ligament length and/or integrity leading to laxity on examination. Grade III injuries involve a complete rupture of the ligament and marked laxity on examination. For example, a submission hold that stresses the elbow may injure the collateral ligaments. Valgus and varus stress testing may reveal laxity or pain which may help the ringside physician pinpoint the injured ligament and the extent of ligament injury.

Strength testing is useful to determine muscle and tendon injuries (strains). Muscle injuries are graded from I to III. Grade I muscle injuries involve pain that increases with isolated contracture of the involved muscle and represent microscopic injuries with no loss of strength. Grade II muscle injuries involve similar findings, but with a distinctive loss of strength. Grade IIII injuries involve a complete tear of the muscle and physical examination reveals a complete loss of strength.

Specialized diagnostic maneuvers are the most helpful when they are used in combination. For example, impingement injuries to the supraspinatus tendon are more accurately diagnosed when both the Neer and Hawkins impingement tests are positive. There are a number of different specialized diagnostic maneuvers for orthopedic injuries. However, it is beyond the scope of this manual to include the extensive list of diagnostic maneuvers. Nevertheless, it is incumbent upon every ringside physician to, at the very minimum, familiarize him/herself with basic maneuvers for use in evaluation of the shoulder, elbow and knee joints.

The triage and emergent treatment of orthopedic injuries naturally follows a careful diagnostic assessment. Most soft tissue injuries do not require immediate care other than rest, ice and analgesics. Contusions are generally self, limited and heal well with time. Underlying fractures should be considered if the contusion overlies a bony structure, such as the zygomatic arch. Most contusions occur on the facial structures, the thighs and the arms. Most grade I and grade II muscle injuries heal well with conservative measures. Grade III muscle injuries may require surgical care and should be referred to a specialist. Similarly, grade II and III ligament and tendon injuries usually require specialized care to avoid long-term impairment. The fighter should follow up with a sports medicine specialist or an orthopedist within a few day of a bout if such an injury occurs.

Joint injuries may involve dislocations. The shoulder is the most commonly dislocated joint with the majority occurring anteriorly. All joint dislocations can involve injury to neurovascular structures and the examination should assess neurovascular function distal to the injured joint. The results of this examination should be well documented. If the ringside physician if familiar with joint reduction techniques, emergent reduction of the injured joint should be attempted, since reduction is frequently easier to achieve immediately after injury before the injured tissues become edematous. Rapid joint reduction may provide immediate relief for the athlete. Steady in-line traction is the preferred method of joint reduction. High leverage maneuvers should be avoided at ringside because of the increased risk of injury. Neurovascular impairment requires an emergent joint reduction attempt. In the absence of neurovascular impairment, the joint may be splinted and the athlete transported to the nearest emergency room for reduction.

Similar to joint dislocations, fractures may involve injury to the neurovascular structures distal to the injured area. Fractures are not usually reduced ringside unless neurovascular impairment is evident. The most commonly occurring long bone fractures involve the metacarpal and metatarsal bones. The fractured area is usually splinted and the athlete transported to the emergency room.

Facial Lacerations in Combat Sports

Contributors:
Sheryl Wulkan, M.D.
Mariel Eliza, M.D., Chair Plastic Surgery Department,
ProHEALTHCare Associates

FACIAL LACERATIONS:

Facial lacerations are common among combat sports athletes. Fortunately, the drama of the bleed usually exceeds the long-term risks of the injury. In mixed martial arts, lacerations may be the end result of attacks by punches, kicks, and knees, but most commonly, elbow strikes. In boxing, many cuts are the result of accidental head butts, or punches that cause compression of the skin and subcutaneous tissues against the bony structures of orbit. The end result is a "blast-type" injury. Note that the greatest damage occurs closest to the point of impact, in the supporting structures BENEATH the surface. The skin laceration is merely the "tip of the iceberg", occurring only when the forces generated exceed the bursting strength of the skin.

RING (CAGE) SIDE EVALUATION

It is imperative that the ringside physician has a large supply of gauze and a hazardous waste bag ring (cage) side.

A referee may stop the action to have the doctor evaluate a cut. In that case, the wound is balloted. The temptation to treat must be avoided; even the application of pressure may be viewed as bias on the doctor's part. The affected area must then be assessed for the type of bleed (arterial or venous), the location of the injury, the depth of the wound, and whether an underlying fracture co-exists.

Indications to stop the bout include:

1. Type of bleed – Arterial bleeding
2. Cut location – Lacerations overlying nerves (usually the supraorbital or infraorbital nerves, involving the lacrimal duct (may also be affected with fractures of the bridge of the nose), the eyelids (especially if the tarsal plate is involved), and full thickness cuts of the vermillion of the lip.
3. Length and depth of the lesion – Remember, the area of damaged tissue is greater than the superficial tear in the skin.
4. The effect the cut has on the fighter's vision – Profuse bleeding can affect a fighter's ability to defend him/her self by obscuring his/her vision. In mixed martial arts, uncontrolled bleeding may obscure an opponent's vision. If the injured competitor is in the superior position on the ground, blood may drip directly into the opponent's eyes.

TREATMENT:

Ringside physicians may or may not be allowed to suture lacerations at the event site. The statutes vary from jurisdiction to jurisdiction. Some Commissions only allow Board Certified Plastic Surgeons to close facial wounds. The ring (cage) side physician must also be cognizant of the legal atmosphere in his/her jurisdiction. If the event is occurring in a large city with many trauma centers and teaching hospitals, it may be unwise for an internist sitting ring (cage) side to suture, no matter how experienced. In contradistinction, the ringside physician may be required to suture if an event is occurring in a more remote setting.

Skin is a multi-layered structure that should be stitched in several separate layers when injured. Otherwise, an unstable scar may develop, which will be more susceptible to re-injury when struck again in the future. Therefore, a physician comfortable with suturing should bring, at minimum, absorbable and non-absorbable suture materials, sterile gloves, several sets of suturing instruments, local anesthetic, a good light source, antiseptic, sterile gauze, and sterile drapes.

SUSPENSIONS/RETURN TO PLAY

The normal skin healing sequence is as follows:

* At 2 weeks the wound has achieved about 20% of its pre-wound strength.
* By 5 weeks it is at about 50%.
* By 10 weeks it is at about 80% of pre-wound strength.
* Remodeling and maturation of the scar will continue for a year or more.
  A minimum of three months (90 days) is required for properly treated cuts to heal prior to subsequent unprotected fights.

Suspensions vary on a case-by case basis, depending on the location and severity of the injury.

In general, lacerations require 4-6 weeks of healing after appropriate suturing before return to sparring. A minimum of 12 weeks' healing time is required before full contact without headgear resumes.

Participants who undergo facial reconstruction requiring an orbital plate should be restricted from sparring for a minimum of 12 weeks.

Author:
Sheryl Wulkan, M.D.
ABC Medical Chair

Editors:
Alan Freedman, M.D.
Mariel Eliza, M.D.

Participant Release of Information Form

ABC CONSENT FORM FOR RELEASE OF MEDICAL RECORDS

I am a combative sports contestant and hereby wish to allow the viewing of my medical records by the
(Appropriate Athletic Commission) for licensing, matchmaking, suspension and other purposes.

I hereby authorize the release of my medical records to the (Appropriate Athletic Commission and the administrators of the ABC Medical Data Bank). I understand that I am waiving privacy protections afforded to me under the H.I.P.A.A and other applicable laws. My signature below constitutes my consent and request to release my medical records to the (Appropriate Athletic Commission and the Administrators of the ABC Medical Data Bank).

I, the undersigned, state that a photostat copy of this authorization will be considered as effective and valid as the original.

Printed Name:_____

Signature:_____

Date Signed:_____



Pre-Participation Medical Clearance Forms

ABC PRE FIGHT PHYSICAL EXAMINATION: COVER LETTER

To: The physician evaluating the participant for combat sports competition

Re: Explanation of Requirements for Clearance

The ABC recommends that a complete physical examination be performed on every combat sports participant because of the rigorous nature of the competition. Punching, kicking, knees and elbows may be used to strike most parts of the body, including the head, depending on the type of event. Sometimes the apparent physical fitness of these athletes lulls us into believing they are the epitome of health, when in fact, this may not the case.

For those doctors who may be less familiar with this type of competition, frequent medical issues that may plague combat sports participants include communicable diseases, complications from performance enhancing drugs (including, hypertension, abnormal hemoglobin/hematocrit, abnormal liver function tests) and dehydration as a result of weight cutting with concomitant electrolyte abnormalities). Please remember that a high normal pulse rate may be abnormal for a well -conditioned athlete, and may be an early indicator of the severity of weight cut necessary for an event. It may also indicate the use of thyroid hormone or other stimulants as a method of facilitating weight loss. It is necessary to take a DETAILED concussion history, including possible loss of consciousness secondary to motor vehicle accidents, street fights, and school or bar brawls. The ophthalmologic history should include questions concerning eye surgery, specifically Lasik, lens implants, retinal surgery or orbital floor reconstruction. Any abnormalities found either by history or physical examination require a detailed explanation and relevant work-up as is customary for the standard of care in your state, tribal commission, or province.

Should you have any questions regarding fighter clearances, please

feel free to contact the ABC medical Committee at:

medcomm@abcmedinfonet.com or swulkan@abcmedinfonet.com.

Thank you for your cooperation.

Respectfully,

The Members of the ABC Medical Committee

ABC PHYSICAL EXAMINATION FORM FOR COMBAT SPORTS ATHLETES

PLEAE NOTE: The ABC medical committee strongly recommends that a licensed physician familiar with the rigors of combat sports complete this medical.
For a list of physicians who are ABC affiliates, please visit either the ABC Medical Committee website (ABCmedinfonet.com) or the ARP website.
(websites to be added if the committee approves).

VITAL SIGNS:

BP:____/____ Pulse:_____
Pulse after 10 jump squats:_____Resp:_____Temp:_____Wt:_____

HEENT:	Normal/Neg	Abnormal/ Comment
EOMI		
PERLA		
Nystagmus		
Scars/ecchymoses		
Turbinates/hematoma		
Throat		
Nodes		
Thyroid		

LUNGS/CHEST WALL	Normal/Neg	Abnormal/ Comment
Pectus excavatum		
Pectus carinatum		
Symmetrical		
Rib tenderness/ribs intact		
masses/nipple discharge/piercings		
Auscultation/percussion		

CARDIAC:	Normal/Neg	Abnormal/Comment
Regular rhythm		
Resting pulse appropriate for athlete		
Ectopy		
Murmur		

ABDOMEN:	Normal/Neg	Abnormal/Comment
Bowel sounds + x 4		
Soft/ non-tender		
Organomegaly		
Hernia		

Skin:		

SKIN:	Normal/Neg	Abnormal/ Comment
Cellulitis		
Alopecia		
Scars		
Piercings		
Pulses(brachial/radial/fem/DP)		

BACK:	Normal/Neg	Abnormal/Comment
curvature		
ROM		
Tendernesss		

ORTHO: (circle affected body part(s)	Normal/Neg	Abnormal/Comment
Muscle symmetry/ atrophy		
NECK/SHOULDERS/ WRISTS/HANDS/DIGITS/ HIPS/KNEES/ANKLE/FT		
a. Tenderness		
b. Edema		
c. Ecchymoses		
d. ROM		
e. Fracture/Dislocation	_____	_____
f. Contusions		

Neuro:	Normal/Neg	Abnormal/Comment
Alertness		
Orientation x 3		
DTR: (biceps/triceps/patellar)		
Babinski		
Rhomberg		
Finger to nose		
Heel to shin		
Abnormal Movements		
a. Tics		
b. Choreiform		
c. Fasciculations		

Genitalia: Male	Normal/Neg	Abnormal/Comment

Herpes gladiatorum				Deferred (circle if applicable)		
Rashes				External		
Open lesions				Testicular mass		
				Varicocoele		
				Lesions		
				Hernia		
				External hemorrhoids		
				FEMALE:		
				Deferred (circle if applicable)		
				Breast masses, dimpling, nipple discharge, piercings		
				Implants: if yes, saline or silicone; age of impllants		
				Pelvic masses		
				Lesions external genitalia		
				Results preg test/date		

TEST RESULTS:

EKG: Date of examination: (Please fill out attached EKG report)
HIV: Date of examination:_____Test result:_____
Hep BsAg: Date of examination:_____Test result:_____
Hep BcAg: Date of examination:_____Test result:_____
Hep BsAb: Date of examination:_____Test result:_____
Hep C A: Date of examination:_____Test result:_____

COMMENTS:_____
_____
_____ .

☐ _____*(participant's name) has been medically cleared for combat sports participation.*
☐ _____*(participant's name) has NOT been medically cleared for combat sports participation.*
☐_____*(participant's name) requires the following tests/consultations PRIOR to obtaining medical clearance.*

*Please list tests/consultations required*_____
_____ .

*Physician's name:*_____*Physician's Signature:*_____*/Stamp*
*Address:*_____
Tel:_____Fax:_____Date of Exam:_____

ABC EKG INTERPRETATION CHECKLIST

NAME:_____ EXAM DATE:_____
ADDRESS:_____
CITY:_____ STATE:_____ COUNTRY:_____

EKG INTERPRETATION:

☐ NSR
☐ Sinus Bradycardia
☐ Sinus tachycardia
☐ Sinus Arrest
☐ Sinus Arrhythmia
☐ S-A Block

☐ SVT
☐ PAC's

☐ Atrial fibrillation
☐ Atrial flutter
☐ Junctional rhythm
☐ PVC's
☐ Ventricular tachycardia
☐ 1° A-V Block
☐ Mobitz Type I
☐ Mobitz Type II
☐ Complete block
☐ QRS>.10

☐ LAD
☐ LBBB
☐ Incomplete RBBB
☐ RBBB
☐ LVH
☐ LVH/repolarization changes
☐ RVH
☐ RVH/repolarization changes
☐ cor pulmonale
☐ Infarct pattern
☐ Ischemic T wave abn
☐ Non-sp ST-Twave ab
☐ Prolonged Q-T
☐ Abnormal P wave
☐ ? Electrolyte abn
☐ Technically limited
☐ Un-interpretable

PHYSICIAN'S DECLARATION:

☐ I, Dr._____, am Board Certified in _____. I have read this EKG as NORMAL.

☐ I, Dr. _____, am Board Certified in_____. The EKG findings are abnormal. The following tests are required prior to consideration for combat sports participation clearance _____
_____
_____.

Signature *Date* *Stamp*

ABC NEUROLOGIC EXAMINATION ACKNOWLEDGEMENT

This examination is required for licensure and renewal of licensure for any ABC participating jurisdiction.

I understand:

1. That the purpose of the screening examination is to detect possible early neurologic changes resulting from repeated head trauma which may occur over extended periods of time secondary to training and competition. These changes may affect my ability to engage in combat sports. This examination may discover neurologic abnormalities that could potentially hinder my ability to defend myself during competition.

2. That this examination does not predict possible future changes such as dementia, language problems and/or difficulties with movement or coordination.

3. That this examination does not mean that you will not sustain head trauma during competition (for example, a bleed on or around the brain)

4. That the physician who is conducting this examination is a board certified, licensed neurologist or neurosurgeon.

5. That all findings from this examination be forwarded to the appropriate Commission and to the medical directors of the ABC Medical Committee medical database. Joan Pierce **Phone: 888-585-9875 or 856-575-4835 Fax: 856-453-1218 email: pierceJ@sjhs.com**

6. That any additional diagnostic procedures or treatment, including those which may be necessary for licensure as determined by the commission for the diagnosis and treatment of any physical or mental condition I may have, will only be done at my request and at my expense, and that the findings of further testing may preclude me from participation in future combat sports competition.

I have read and understand my obligations as outlined in the statements above.

SIGNATURE OF APPLICANT DATE

ABC MEDICAL CHECKLIST: TRAUMATIC BRAIN INJURY

To the radiologist performing the MRI,

The following checklist should be used to assist in compliance with current ABC Medical Requirements for all Combat Sports Participants. Please remember to re-assess the athlete's "MRI compatibility" prior to performing this test. Please also note the study should utilize an MRI with 1.5T or greater, and must include gradient or SWI images to assess for shearing injury. Thank you for your cooperation.

The radiologist reading the study should use the following checklist while reading the study:

PATIENT INFORMATION:

NAME: _____

DOB: _____ Date of Examination: _____
Month Day Year Month Day Year

Traumatic Brain Injury (TBI) Associated Findings on 1.5T or greater MRI				
Hippocampal atrophy	None	Mild	Moderate	Severe
	☐	☐	☐	☐
Cavum septum pellucidum	None	Mild	Moderate	Severe
	☐	☐	☐	☐
Increased lateral ventricle size	None	Mild	Moderate	Severe
	☐	☐	☐	☐
Dilated perivascular spaces	None	Grade I	Grade II	Grade III
	☐	☐	☐	☐
Shearing injury (DAI)	Absent	Present	Number of Lesions	
	☐	☐		
Cerebral atrophy	Absent	Present		
	☐	☐		
Pituitary gland atrophy	Absent	Present		
	☐	☐		
Contusions	Absent	Present		
	☐	☐		

Updated 03/2009
Saved as: MRI-MRAorder in word Medical Forms & Info file

ABC OPTHALMOLOGY HISTORY FORM

NAME:.....**DOB:**.....**AGE:**.....
LAST FIRST MIDDLE Month/Day/Year

ADDRESS:.....

HISTORY:

	YES	NO
Have you ever had any of the following:	☐	☐
1- Blurred or decrease in vision	☐	☐
2- Surgery to either eye (or surrounding area)	☐	☐
3- Laser to either eye		

If yes, please explain:

_____

_____

_____

_____.

Have you ever been informed by doctor that you have had:	YES	NO
1- Retinal Tear	☐	☐
2- Retinal Hole	☐	☐
3- Retinal Detachment	☐	☐
4- Cataract	☐	☐
5- Glaucoma	☐	☐
6- Dislocated Lens	☐	☐
7- Keratoconus or any corneal condition	☐	☐
8- An inherited disease that could affect the eyes	☐	☐

Have you ever had an eye injury: **YES** **NO**

If yes, please explain:_____

_____

_____

_____

_____.

Do you have any history of having any problems **YES** **NO**

or issues with your eye(s):

If yes, please explain:

_____

_____

_____

_____

_____.

Have you ever had any laser or surgical correction (refractive surgery) to your eyes:

(ie, LASIK, PRK, RK, intrastromal rings) **YES** **NO**

If yes, please explain:

_____

_____

_____

_____

_____.

Do you wear: Eyeglasses: _____ Contact Lenses: _____

(Circle one if applicable)

- Soft contacts
- Hard contacts

ABC OPTHALMOLOGY EXAMINATION FORM

FIGHTER'S NAME: _____

DATE (Month/Day/Year): _____

EXAMINATION:

VISION	Without Glasses	Best Corrected
Right (OD)		
Left (OS)		

REFRACTION (for distance):

Right (OD)	
Left (OS)	

EYE PRESURE (Tension): **METHOD USED:** _____

mm Hg

Right (OD)	
Left (OS)	

PUPILS: _____

EXTRAOCULAR MOVEMENTS: _____

STEREOPSIS: _____

ABC OPHTHALMOLGY EXAMINATION FORM

SLIT LAMP EXAMINATION:

	NORMAL		ABNORMAL	
	Right	**Left**	**Right**	**Left**
Lids/Lashes				
Cornea				
Conjunctiva				
Ant Chamber				

Gonioscopy:

Right (OD)	
Left (OS)	

Dilated Fundus Examination Results:

	NORMAL		ABNORMAL	
	Right	**Left**	**Right**	**Left**
Disc				
Macula				
Vessels				
Perioheral retina				

Please provide further commentary about any abnormalities found in the space provided below. Include suggested treatment plan, if required, and your opinion as to the immediacy of any intervention deemed necessary.

_____

_____

_____

_____.

ABC OPTHALMOLOGY EXAMINATION FORM: Physician's Declaration

EXAMINING PHYSICIAN:

☐ **Based on the history and ophthalmologic examination, I believe that this applicant should be allowed to participate in combat sports.**

☐ **Based on the history and ophthalmologic examination, I DO NOT believe that this applicant should be allowed to participate in combat sports.**

☐ **Based on the history and ophthalmologic examination, I believe medical/surgical intervention is necessary with follow –up in _____ _____(time period) prior to clearance.**

I certify that I am a licensed ophthalmologist in good standing in the state/jurisdiction of _____.

_____ _____

Physician's Name Medical License Number

_____ _____

Physician's Signature Date (mo/day/yr)

_____

(Street Address) City State Zip Code

Fight Night Forms

FIGHT NIGHT CHECK LIST

1. A physician should be assigned to notify the nearest hospital and trauma center (if not the same) that a combat sports event is taking place. The neurosurgeon on call should also be notified in advance of the event, especially in more remote settings, where physician travel time may be the difference between a good or catastrophic outcome.

2. All ring(cage)side physicians should have the phone numbers of both the neurosurgeon and the nearest trauma center's emergency room on speed dial.

3. The lead physician should make sure the ambulance is on site. The ring(cage)side doctors should discuss the venue's egress route with the EMT crew in anticipation of a serious injury. A "walk through" of this route should be done to ensure there are no unanticipated problems. If an elevator is necessary for evacuation, make sure security designates it for the sole purpose of this event. Confirm that the elevator is large enough to accommodate a stretcher and necessary medical personnel. Notify security of the evacuation plans so that they can help facilitate evacuation by maintaining crowd control if warranted.

4. The doctors and EMTs should check the oxygen tank to ensure it is working appropriately. In addition to oxygen, an adult mask, collar and board should be placed ring(cage)side.

5. The physicians should talk with the referee to decide upon the best method for communicating concerns about a fighter, if any, during a bout.

6. The ringside doctors should check all required medical equipment prior to the event's onset. A hazardous waste bag should be available ring(cage)side for disposal of used gloves and bloody gauze.

7. The physician should order the pre-fight physicals by bout. The physician should also make sure he/she is in possession of suspension and

insurance forms prior to the onset of the fight. Suspension forms should be prepared in duplicate (one for the commission, one for the participant).

8. Designate a room for post-fight physicals prior to the onset on the event.

9. Check locker rooms after the event.

ABC Physician Fight Night Check-List

	Yes	*No*	*N/A*
Hospital number on lead physician's speed-dial			
ER contacted about event/neurosurgeon on call			
Pre-fight/Post fight forms available			
Insurance forms available			
Ambulance on site			
Discussion with ambulance personnel: your expectations re their role in evacuation protocol. Make sure oxygen tank full, collar, mask and board available.			
Walk through evacuation route. Make sure elevators functional/stretcher fits.			
Second ambulance available?			
Introduce yourself to inspectors. Make sure they know to keep everyone out of cage when knock-out occurs (except translators if necessary)			
Identify fighters whose first language is something other than English. Work with Commission to pre-determine who will act as translators for the event.			
Discuss with referee communication technique(s)			
Equipment check			
Ringside seating: access to cage or ring suitable			
Secure room for post-fight evaluation, treatment, and, if necessary, observation			
Check locker rooms post fight for last-minute issues			

ABC MEDICAL SUSPENSION REPORT

_____ *is medically suspended for a period of*
_____ *days, beginning (date of event)*_____ .

SUSPENSION TIME (# of days)	**No Contact/Sparring** (# of days)
30	14
45	30
60	45
90	60
180	120
360	210
Indefinitely pending requested testing	
Permanently	

The cause of the suspension is the following:

☐ KO * ☐ TKO * ☐ Excessive Head Trauma * ☐ Medical * ☐ Laceration
☐ Orthopedic Injury * ☐ Other

REQUIRED TEST(S):

☐ Examination by a neurologist * ☐ CT of the head * ☐ CT of facial bones
☐ Examination by an ophthalmologist * ☐ Examination by an orthopedist
☐ Other_____

RECOMMENDED TIMING OF TEST(S):

☐ Immediately * ☐ Within 12-24 hrs. * ☐Within 7 days * ☐ Within 30 days
☐ NO LATER THAN 10 DAYS PRIOR TO YOUR NEXT FIGHT.

Please submit the required medical reports/clearance letters to the jurisdiction in which you were suspended AND to the ABC Medical Records Chair, Dr. Robert Smick. Both Dr. Smick and Joan Pierce, R.N., may be reached at:

Phone number: 888-585-987 or 856-575-4835 Fax number: 856-453-1218 *email:* ***pierceJ@sjhs.com***

THE SUSPENSION WILL BE POSTED ON THE NATIONAL SUSPENSION REGISTRY. A FINAL DETERMINATION REGARDING REINSTATEMENT WILL BE MADE BY THE JURISDICTION IN WHICH YOU WERE SUSPENDED.

SIGNATURE
BOXER:_____ MANAGER_____ PHYSICIAN_____

Therapeutic Use Exemption Forms (TUEs)

THERAPEUTIC USE EXEMPTION ("TUE") PROGRAM

A. Standard

Participating combatants who use or possess a Prohibited Substance for which they have a valid, medically appropriate prescription issued by a duly licensed physician in the United States or Canada will not violate the "TUE" Program.

B. Procedure

To obtain a TUE, a participating combatant who may be subject to a pre/post-fight mandatory test should fax or mail a copy of their prescription to the commission hosting the event. All other participating combatants do not need to apply for a TUE before a drug test is conducted. The TUE will then be evaluated and reviewed by a designated commission physician.

Each commission may request that additional medical documentation be provided to support a TUE application. All medical information provided to the commission will be kept strictly confidential and will not be disclosed to anyone other than the members of local commission or Association of Boxing Commissions (ABC). The commission physician will notify local commissioner and the participating combatant whether the application for a TUE has been approved. Unless the commission physician determines otherwise, the maximum effective period of a TUE for the approving commission is one year. A TUE is not automatically renewed. A participating combatant must apply for a renewal of the TUE if he or she is still taking the prescribed medication on an annual basis. The decision of the commissioner will be final.

C. Prohibited Drugs of Abuse

PROHIBITED SUBSTANCES UNDER THE TUE PROGRAM

Participating combatant are strictly prohibited from using, possessing, distributing or selling Prohibited Substances. Prohibited Substances under the Program include Drugs of Abuse and Performance Enhancing Substances as described below:

A. Drugs of Abuse

Any and all drugs or substances included in Schedules I and II of the Code of Federal Regulations' Schedule of Controlled Substances, as amended from time to time, shall be considered a Drug of Abuse covered by the Program (excluding those Schedule I and II substances included as Performance Enhancing Substances below). Moreover, any drug or substance that is not included in either Schedule I or II shall be considered a Drug of Abuse if it:

(i) is similar in nature to a substance in Schedule I or II; (ii) cannot be lawfully taken without a valid prescription and has the potential for abuse; or (iii) cannot be lawfully obtained or used in the United States. The following is a non-exhaustive list of Drugs of Abuse covered by the Program:

1. **Cannabinoids** (*e.g.,* **THC** and **Marijuana**)
2. **Cocaine**
3. **LSD**
4. **Opiates** (*e.g.,* **Heroin**, **Codeine**, and **Morphine**)
5. **MDMA** (**Ecstasy**)
6. **GHB**
7. **Phencyclidine** (**PCP**)

B. Performance Enhancing Substances
The following substances shall be considered Performance Enhancing Substances under the Program. Some Performance Enhancing Substances are available for over-the-counter purchase or with a prescription in the United States or other counties. Unless a participating combatant successfully obtains a Therapeutic Use Exemption in accordance with the provisions of the TUE Program, a participating combatant will not be excused from a positive test because the Performance Enhancing Substance was obtained over-the-counter or through a valid prescription.

1. **Anabolic Androgenic Steroids ("AAS")**
Any and all AAS included in Schedule III of the Code of Federal Regulations' Schedules of Controlled Substances ("Schedule III") shall be considered a Performance Enhancing Substance covered by the Program. AAS that are not included in Schedule III but that may not be lawfully obtained or used in the United States (including "designer steroids") shall also be considered Performance Enhancing Substances covered by the Program. The following is a non-exhaustive list of AAS that are covered by the "TUE" Program:

1. **Androstadienedione**, **Androstanediol**, **Androstanedione**, **Androstenediol**, **Androstenedione**, **Androsterone**, **Bolandiol**, **Bolasterone**, **Boldenone**, **Boldione**, **Calusterone**, **Clostebol**, **Danazol**, **Dehydrochlormethyltestosterone (Turinabol)**, **Dehydroepiandrosterone (DHEA)**, **Desoxymethyltestosterone (DMT, Madol)**, **Dihydrotestosterone**, **Drostanolone**, **Epiandrosterone**, **Epi-dihydrotestosterone**, **Epitestosterone**, **Ethylestrenol**, **Fluoxymesterone**, **Formebolone**, **Furazabol**, **Gestrinone**, **4-Hydroxytestosterone**, **Mestanolone**, **Mesterolone**, **Methandienone**, **Methandriol**, **Methasterone (Superdrol)**, **Methenolone**, **Methyldienolone**, **Methylnortestosterone**, **Methyltestosterone**, **Methyltrienolone (Metribolone)**, **Mibolerone**, **Nandrolone**, **Norandrostenediol**, **Norandrostenedione**, **Norandrosterone**, **Norbolethone (Genabol)**, **Norclostebol**, **Norethandrolone**, **Noretiocholanolone**, **Oxabolone**, **Oxandrolone**, **Oxymesterone**, **Oxymetholone**, **Prasterone (DHEA)**, **Prostanozolol**, **Quinbolone**, **Stanozolol**, **Stenbolone**, **Testosterone**, **Tetrahydrogestrinone**, **Trenbolone**, and any other substances with a similar chemical structure or biologic effect(s).

2. **Stimulants**

All Stimulants (including both their D and L isomers where relevant) are prohibited. The following is a non-exhaustive list of Stimulants that are covered by the "TUE" Program:

Andrafinil, **Amfepramone**, **Amiphenazole**, **Amphetamine**, **Amphetaminil**, **Armodafinil**, **Benfluorex**, **Benzphetamine**, **Benzylpiperazine**, **Bromantan**, **Carphedon**, **Cathine (Norpseudoephedrine)**, **Chlorphentermine**, **Clobenzorex**, **Clortermine**, **Cropropamide**, **Crotetamide**, **Ephedrine**, **Etamivan**, **Etilamphetamine**, **Etilefrine**, **Famprofazone**, **Fenbutrazate**, **Fencamine**, **Fencamfamin**, **Fenethylline**, **Fenfluramine**, **Fenproporex**, **Furfenorex**, **Heptaminol**, **Isometheptene**, **Levmetampetamine**, **Meclofenoxate**, **Mefenorex**, **Mephentermine**, **Mesocarb**, **Methamphetamine (Methylamphetamine)**, **Methylenedioxyamphetamine**, **Methylenedioxymethamphetamine**, **Methylephedrine**, **Methylhexaneamine (Dimethylamphetamine)**, **Methylphenidate (Ritalin)**, **Modafinil**, **Nikethamide**, **Norfenefrine**, **Norfenfluramine**, **Octopamine**, **Oxilofrine**, **Parahydroxyamphetamine**, **Pemoline**, **Pentetrazol**, **Phendimetrazine**, **Phenmetrazine**, **Phenpromethamine**, **Phentermine**, **Prenylamine**, **Prolintane**, **Propylhexedrine**, **Selegiline**, **Sibutramine**, **Strychnine**, **Tuaminoheptane**, and any other substances with a similar chemical structure or biologic effect(s).

3. Miscellaneous Anabolic Agents

Including, but not limited to, **Clenbuterol**, **Selective Androgen Receptor Modulators (SARMs)**, **Tibolone**, **Zeranol**, and **Zilpaterol**.

4. Hormones and Related Substances

The following substances and their releasing factors are prohibited:
1. **Human Growth Hormone** (**HGH**);
2. **Insulin-Like Growth Factors** (*e.g.,* **IGF-1**);
3. **Mechano Growth Factors** (**MGFs**);
4. **Gonadotrophins**, including but not limited to, **Human Chorionic Gonadotrophin** (**hCG**), and **Luteinizing Hormone** (**LH**);
5. **Erythropoisis-Stimulating Agents** (*e.g.,* **Erythropoietin** (**EPO**), **Darbepoetin** (**dEPO**), **Hematide** and **Methoxy polyethylene glycolepoetin beta** (**CERA**));
6. **Corticotrophins**;
7. Other substances with similar chemical structure or similar biological effect(s).

5. **Hormone Antagonists and Modulators**

The following classes of substances are prohibited:
1. **Aromatase Inhibitors** including, but not limited to, **Anastrozole**, **Androstatrienedione (ATD)**, **Androstenetrione** (**6-OXO**), **Aminoglutethimide**, **Dianastrozole**, **Exemestane**, **Formestane**, **Letrozole**, and **Testolactone**.

2. **Selective Estrogen Receptor Modulators** (**SERMs**), including, but not limited to, **Raloxifene**, **Tamoxifen**, and **Toremifene**.
3. **Other Anti-Estrogenic Substances** including, but not limited to, **Clomiphene**, **Cyclofenil**, and **Fulvestrant**.
4. **Agents modifying myostatin function(s)** including, but not limited to, **Myostatin Inhibitors**.

6. **Diuretics and other Masking Agents**

Masking agents are defined as products that substitute, dilute, mask or adulterate a specimen urine sample used in drug testing or impair the excretion of Prohibited Substances to conceal their presence in a sample.

1. **Masking agents** include: **Diuretics**, **Probenecid**, **Plasma Expanders**, and other substances with similar biological effect(s).
2. **Diuretics** include: **Acetazolamide**, **Amiloride**, **Bumetanide**, **Canrenone**, **Chlorthalidone**, **Etacryrnic Acid**, **Furosemide**, **Indapamide**, **Metolazone**, **Spironolactone**, **Thiazides** (*e.g.,* **Bendroflumethiazide**, **Chlorothiazide**, and **Hydrochlorothiazide**), **Triamterene**, and other substances with similar chemical structure or similar biological effect(s).

D. DENIALS

Denial of the TUE exemption of prohibited substances are at the sole discretion on the local commission and commission physicians.

E. APPEALS

If requested by the participating combatant, and at the sole discretion of local commission, the participating combatant will be afforded a telephone (or in-person) hearing to allow him or her an opportunity to present any evidence or witnesses that he or she believes is relevant to the appeal.

F. CONFIDENTIALITY

The confidentiality of participating combatant's medical conditions, prescriptions and test results will be protected to the maximum extent possible and as required by law. Information submitted to commission physicians in support of a TUE will be disclosed only to members of the local commission and the ABC on an as needed basis and to no other individuals.

ABC THERAPEUTIC USE EXEMPTION FORM

ATHLETE INFORMATION

Surname:_____ First Name:_____

Female: ☐ Male: ☐

Birth Date:_____
Day Month Year

Address: _____

City/Town:_____ Country:_____ Zip(Post) Code_____

National Identificaton Number: _____

Jurisdiction where ID Issued: _____

Telephone:
_____

E-mail: _____

Name Combat Sport in which athlete participates:_____

Weight class: _____

MEDICAL INFORMATION

Diagnosis with sufficient medical information(history, physical, specific diagnostic testing, date first diagnosed, date first treatment (please attach copies of test results).....
.....
.....

.....
.....
.....

If a permitted medication can be used to treat the medical condition, please provide justification for the requested use of the prohibited medication:

.....
.....
.....
.....
..... .

MEDICATION DETAILS			
PROHIBITED SUBSTANCES:	**DOSE**	**ROUTE**	**FREQUENCY**

INTENDED DURATION OF TREATMENT:

- ☐ **....Once only**
- ☐ **....Emergency**
- ☐ **....Duration (approximate):**

MEDICAL PRACTITIONER'S DECLARATION

I CERTIFY THAT THE AFORE-MENTIONED TREATMENT IS MEDICALLY APPROPRIATE AND THAT THE USE OF NON-PROHIBITED ALTERNATIVE MEDICATION(S) WOULD BE UNSATISFACTORY FOR THIS CONDITION.

NAME:.....

ADDRESS:.....

Tel:.....**Fax:**.....

Email:.....

Signature of Medical Practitioner:.....

Date:.....
Month Day Year

Stamp:

ABC THERAPEUTIC USE EXEMPTION FORM

Physician's Declaration

"I, Dr._____, have performed and reviewed the above medical tests on _____(date) and have determined that _____(fighter's name) has _____(condition). The patient has been under my care for_____(period of time) for this disorder. I understand that this patient competes in a sport where inappropriate use of anabolic steroids, growth hormone or other performance enhancing drugs may be grounds for license revocation because such use may be prohibited, banned and/or illegal.

Sign, Date and Stamp

_____

ABC THERAPEUTIC USE EXEMPTION FORM

ATHLETE'S DECLARATION

I,.....certify that the information contained in this document is accurate, and that I am requesting approval to use a medicine or treatment from the ABC Prohibited List. I understand that the list of prohibited substances may be found on the ABC or IAACS website. I authorize the release of personal medical information to the jurisdiction in which I am competing, and agree to have that information archived in the ABC/IAACS medical data bank. Furthermore, I acknowledge that if I every wish to revoke the right of these organizations to obtain my health information, I must notify my medical practitioner and the ABC Medical Committee in writing.

Athlete's signature:.....Date:.....

Parent/Guardian's signature:.....Date:.....
(if competitor is under the age of 18)

DOCUMENTATION REQUIRED TO SUPPORT A THERAPEUTIC USE EXEMPTION APPLICATION

1. *ESSENTIAL SUPPORTING DOCUMENTS: ADD/ADHD*

- A completed, legible TUE application form
- A clinical record of the onset of symptoms and copies of the condition notes leading to the present diagnosis. Please note: The criteria used should be in accord with the most recent edition of the DSM or ICD.
- Other primary records, including special education evaluation records or second expert opinions
- General medical history, including other diagnoses and currently prescribed medications.

DURATION: Any athlete on prolonged therapy with stimulants should provide evidence of annual review by a specialist in the management of ADD/ADHD.

CAUTIONARY MATTERS: Drugs to manage ADHD can potentially cause cardiovascular side effects. It is therefore recommended that relevant physical findings (blood pressure, heart auscultation, EKG, etc.) and, when applicable, the results of any further diagnostic testing deemed necessary by your health care provider, be submitted with the TUE application.

2. *ESSENTIAL SUPPORTING DOCUMENTS: TESTOSTERONE REPLACEMENT THERAPY*

- **A diagnosis of primary or secondary hypogonadism must be clearly established.**
- **The etiology of hypogonadism must be demonstrated.**
- **Include the results from any relevant imaging studies (pituitary tumor, etc.).**
- **Provide results from a physical examination including a description of all symptoms including (but not limited to):**
    - **Incomplete sexual development**
    - **Reduced sexual desire (libido) and activity**
    - **Change in hair pattern (male baldness pattern).**
    - **Small or shrinking testes**
    - **Decrease in spontaneous erections**
    - **Height loss due to vertebral compression fracture**
    - **Low bone mineral density**
    - **Reduced muscle mass**
    - **Reduced muscle strength**
- **Provide at least two separate measurements of baseline testosterone therapy (PRIOR TO ANY replacement therapy)**

- Free or bioavailable testosterone samples should be taken in the morning.
- If an athlete has been on testosterone replacement therapy already, baseline testosterone levels cannot be measured until therapy has ceased for at least two months.
- Levels consistently BELOW the LOWEST LIMIT OF a given laboratory's established NORMAL RANGE must be demonstrated using recognized testing methods such as equilibrium dialysis.
- An internal medicine specialist, D.O., or an endocrinologist must interpret the obtained values.

- Provide LH and FSH values measured concomitantly with testosterone levels.
- Provide results from stimulation of the gonadal axis by hcG.
- Provide confirmation that the athlete does not have any short term illness or other condition that could potentially influence testosterone production at the time of evaluation
- Provide confirmation that the athlete is not taking any medication that may affect testosterone levels.

- Provide a detailed treatment plan including how systemic testosterone levels will be monitored to ensure appropriate levels of testosterone. The plan should include intervals between testosterone level reassessment.

Acknowledgements



Special thanks:

to Tim Lueckenhoff, ABC President, for all his support.

to Nicholas Lembo, for his guidance and assistance with this project.

to Ray Longo, for 15 years of martial arts tutelage and for his unerring friendship.

to my children, Emma and Jareb, whose support (technical and emotional) made this project possible.

to Ray Bailey, for supplying amazing boxing photographs.

to Ray Kasprowicz, for supplying brilliant Muay Thai photographs (Cover photo: Back Elbow), courtesy of Muay Thaimes Magazine.

to Peter Marney, for supplying brilliant Muay Thai photographs (Cover photo: Maqcmhaolin vs. Sidu), courtesy of Muay Thaimes Magazine.

to Charles Penner, for granting us use of the MMA photo of Kim Couture

to Robert Reiter, owner of Muay Thaimes Magazine, for granting us use of the Thai Boxing photographs.

A Pictorial Review Of Mixed Martial Arts Maneuvers for the Ringside Physician

(With Self-Assessment Guide for Commonly Used Terms/Common Injuries)

Contributors:
Photographer: Sheryl Wulkan, M.D.
Text editor: Michael Kelly, D.O.
Athletes: Alexander Iaquinta, Professional Mixed Martial Artist, and
Eric Hyer, Chief Muay Thai Coach, Ray Longo's MMA Academy

*Special thanks to **Ray Longo** for allowing us to use his academy for this project**

◆*Special thanks to **Matt Serra**, former UFC Middleweight Champion, for sharing his advice and expertise* ◆

INTRODUCTION

Understanding "the game" is an essential component of ring (cage) side medicine, since it allows the treating physician to anticipate the type, degree and severity of an injury resulting from strikes, submission holds, or a combination of offensive and defensive techniques. Knowledge of the sport can also help build rapport with, and establish the basis for, good communication skills with the referee. These skills may ultimately diminish the risk of fighter morbidity or catastrophic injury.

An established ring (cage) side physician should be able to identify the majority of drills presented in this addendum. If you are unable to identify at least 60 of these maneuvers, you should consider continuing to act in the capacity of an apprentice at mixed martial arts events before agreeing to sit cage side in an official capacity.

SELF – ASSESSMENT

Directions:

Name the move and identify the most common injuries, if any, associated with it.

IMMA
RAY LONGO'S INTERNATIONAL MARTIAL ARTS ACADEMY
Train Hard
or Go Home
LONGO
PETITION TEAM

2

3



5



6


MMA
Train Hard
or Go Home



8



9



10



11



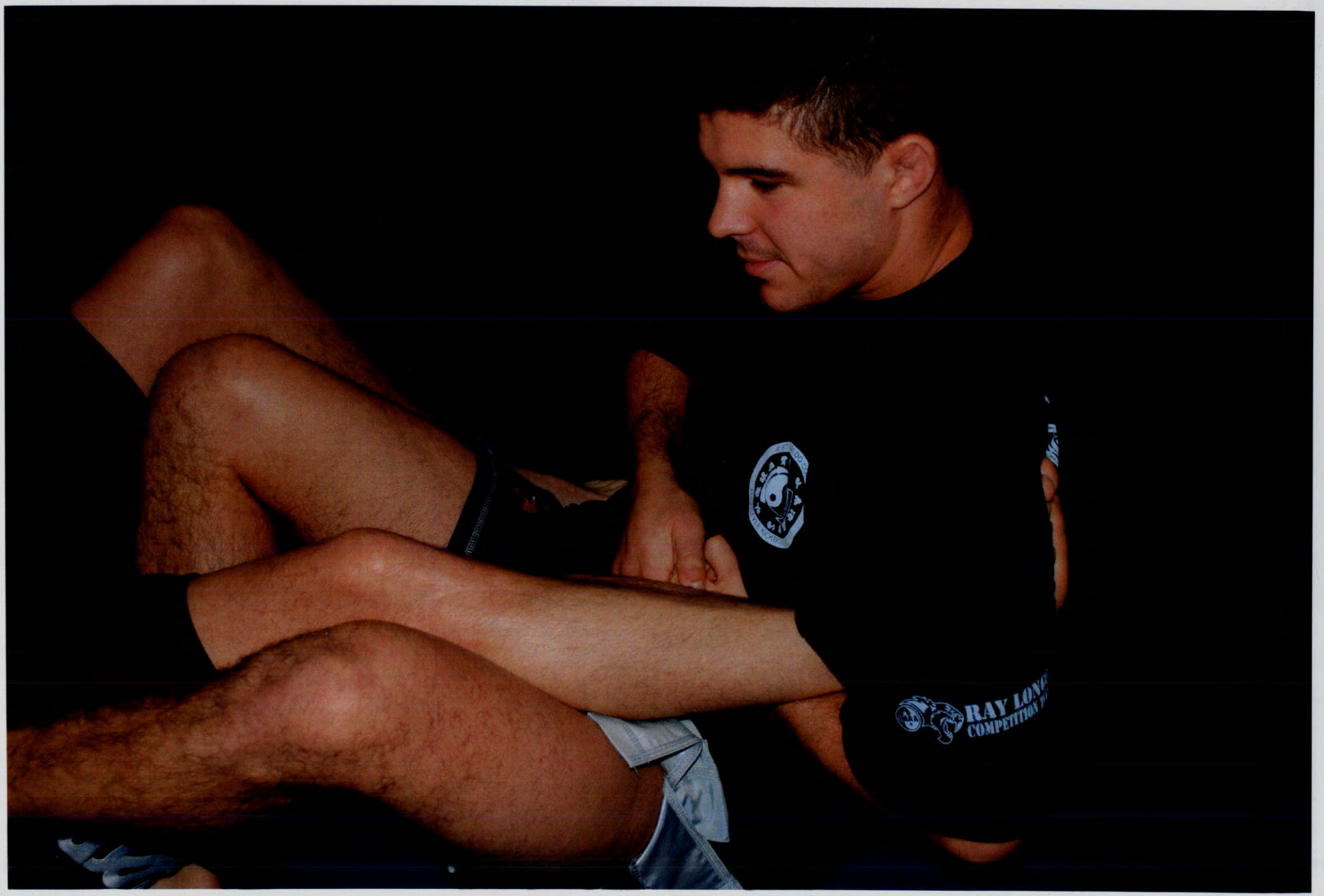
RAY LONG
COMPETITION

14

15

16



17



18

19

20


IMAA
RAY LONGO'S INTERNATIONAL MARTIAL ARTS
Train Hard
or Go Home!



22



23



24

25



27

28



30

31

32

SUPERSTAR


RAY LONGO
COMPETITION TEAM

Go Home!

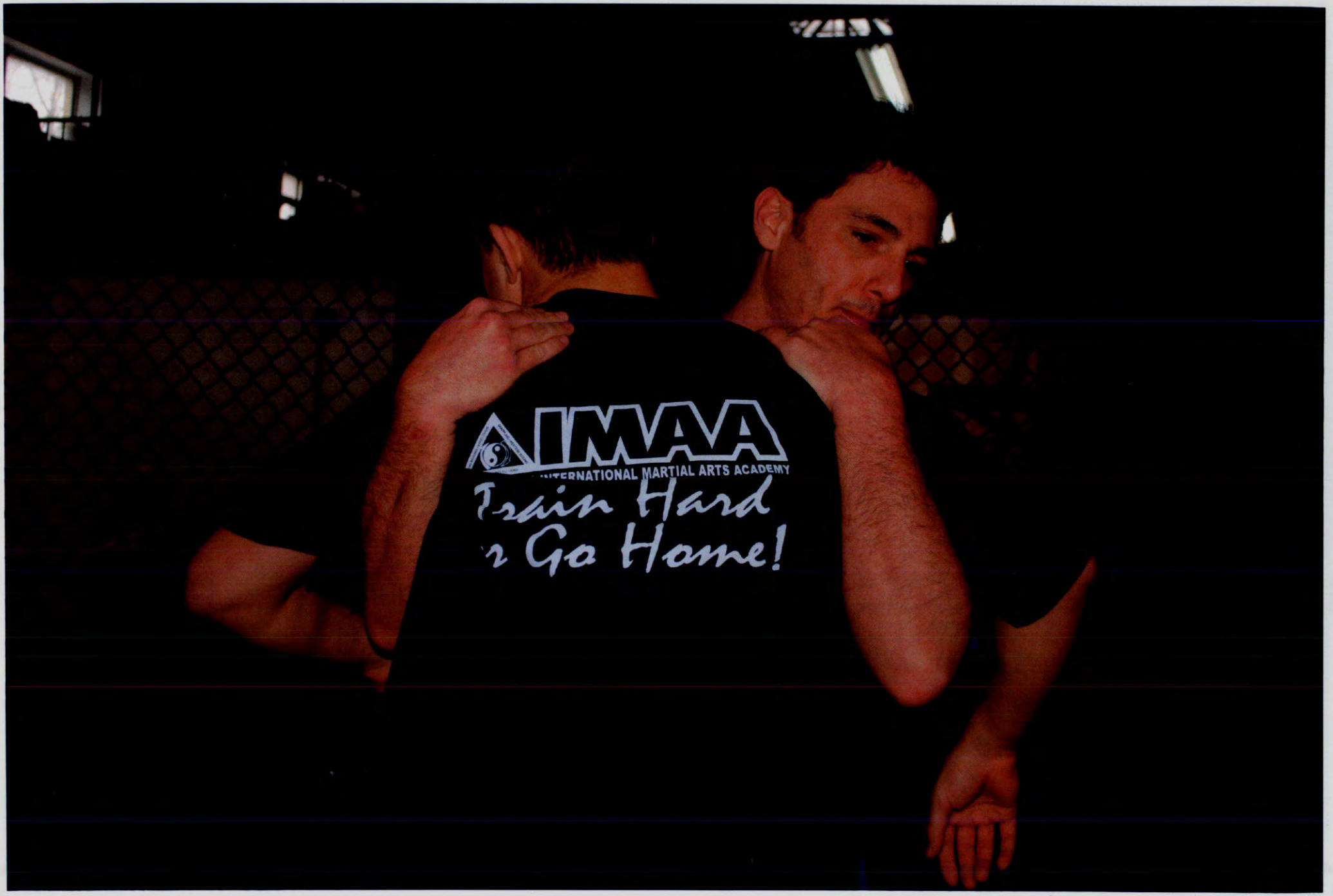
AIMAA
INTERNATIONAL MARTIAL ARTS ACADEMY
Train Hard
2 Go Home!

37

38



39



40

41

42

FACEBOOK.COM/GRAPPLER
GUILLOTINE
SPRAWL

44

45

46

47

48

49


SERRA
JIU-JITSU



15

52


RAY LONGO
COMPETITION
TERRA BJJ
LICPRIZZA
FACEBOOK.COM/CASTORPRIZZA
SPP

53

54



55

56



57

58

59

60

61



62



63


SUPERSTAR
STW
DENTURES

65

66


SUPERSTAR
GRAPHIC
STW
DESIGNS
facebook.com/stwgraphicdesigns
www.stwgraphics.com
RAY LONGO
COMPETITION TEAM



89



69


CASTILLO
SERRA LONGO
HULK
MANAGEMENT INC
LIFETIME
CHIMNEY SUPPLY.COM

70

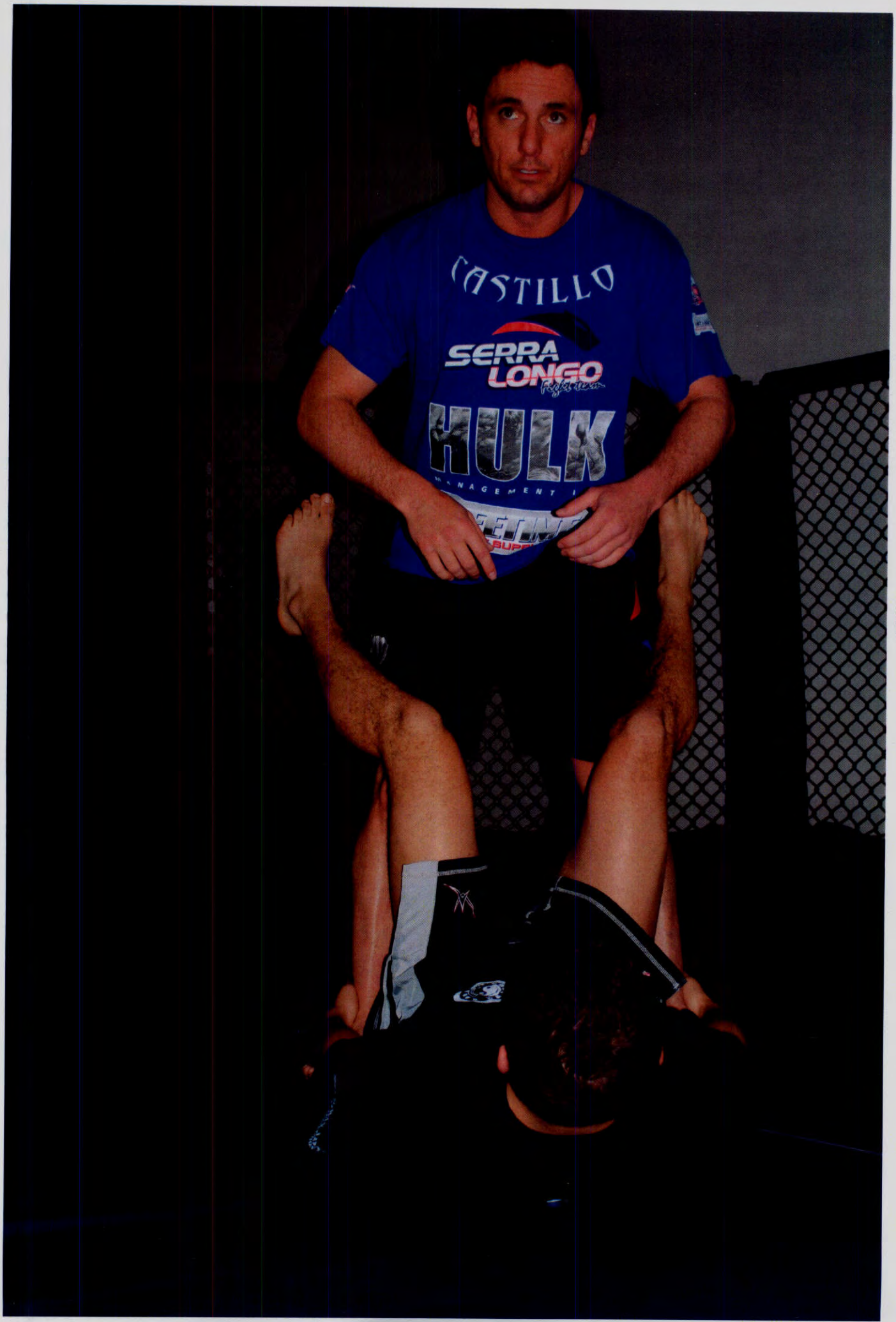

71

SELF ASSESSMENT: Answers

1. DUCK UNDER
Definition: A grappling move in which a fighter "ducks under" the opponent's arm in an attempt to get behind him/her, to position the opponent for a lift, throw, trip takedown or other MMA attack.
Associated injuries: possible neck injuries (cervical strain or sprain)

2. SINGLE LEG TAKEDOWN
Definition: A move in which a fighter takes the opponent down by lifting and controlling one of the opponent's legs.
Associated injuries:

- The Attacker: Flexion injuries (cervical sprains or strains) to the neck, shoulder and possibly back injuries (strains or disc problems)
- The Opponent: Possible wrist injuries (Sprains, strains, tendon tears, dislocations) or finger, wrist, or forearm fractures if unfamiliar with proper falling techniques.

3. DOUBLE LEG TAKEDOWN
Definition: A driving takedown that is executed when a fighter engages another fighter by grasping both of the fighter's legs, generally gripping the back of the fighter's knees and lifting to displace balance.
Associated injuries: as with single leg.

4. DOUBLE LEG TAKEDOWN

5, ARM DRAG
Definition: A method of grabbing, pulling and controlling an opponent's arm in an attempt to throw him/her off balance and gain positional control.
Associated injuries: none

6. ANKLE PICK
Definition: A move in which a fighter takes the opponent down by the grabbing or lifting the ankle of his/her opponent forcing him/her to the ground.

7. ANKLE PICK

8. INSIDE LEG TRIP
Definition: Is a sweeping motion applied when one fighter sweeps or hooks with his/her leg, the inner leg of his/her opponent in an effort to displace the opponent's balance and bring the opponent to the ground.
Associated injuries: Knee, shin or ankle injuries (sprains, strains or fractures) in either competitor if the fall is not controlled.

9. OUTSIDE LEG TRIP

Definition: Is a hooking motion applied when one fighter hooks with his/her leg, the outside leg of his/her opponent in an effort to displace his/her balance and bring the opponent to the ground.
Associated injuries: as above

10. BODY LOCK
Definition: A hold in which a fighter locks his/her arms around the opponent's body as a method of control. The fighter may take the opponent down from this position.
Associated injuries: back and rib injuries

11. WHIZZER
Definition: A defensive technique utilizing under hooks and pressure. This technique is used to prevent a single leg takedown.
Associated injuries: Aggressor: Lumbar sprains and strains, disc injury
Opponent: Shoulder sprains, strains, dislocation

12. HIP TOSS
Definition: A forward throw common to most grappling disciplines where one fighter is thrown over the other fighter's hips.
Associated injuries:

- Attacker: Intercostal muscle and ligament injuries, lumbar sprains, strains and acute lumbar disc herniation.
- Opponent: If opponent falls improperly, wrist injuries, forearm injuries (sprains, strains, dislocations, fractures), elbow injuries (dislocations, UCL tears), neck injuries

13. ACHILLES FOOT LOCK
Definition: A leg lock that applies pressure to the Achilles tendon and calf.
Associated injuries: Achilles tendon strain and rupture.

14. HEEL HOOK
Definition: Attacks the ankle joint. Set up in a similar fashion to the ankle lock, the attacking fighter positions his/her opponent's foot down past the attacking fighter's side. The heel should be just outside the crook of the elbow of the aggressor. The fighter performing the heel hook then applies leverage by pulling the opponent's heel toward his/her nose. The heel is rotated medially in this maneuver.
Associated injuries: Ankle sprain, Achilles tendon injuries, occasionally mid -foot sprains
-
15. INSIDE (INVERTED) HEEL HOOK
Definition: An inverted heel hook is performed by holding the opponent's foot in the attacker's OPPOSITE armpit, and applying pressure laterally.
Associated injuries. Ankle sprains.

16. STRAIGHT KNEE BAR
Definition: A knee bar is a leg lock which hyper-extends the knee. The basic knee bar is performed similarly to an arm bar by holding the opponent's leg in between the legs and arms so the opponent's kneecap points towards the body. The opponent's leg is straightened by pushing the hips forward.
Associated injuries: Usually meniscus tears, ligamentous hyperextension injuries.

17. TWISTER

Definition: Attacks the spine by isolating the legs in one direction and leveraging the head, neck and torso in the opposite direction.
Associated injuries: Intercostal muscle and ligament injuries, lumbar sprains, strains and acute lumbar disc herniation.

18. PERUVIAN NECK TIE
Definition: Is similar to the guillotine choke. The move is performed by placing both hands together in the neck area of the opponent. The arms of the attacking athlete are used to squeeze the neck while the legs are used to trap the opponent's far side arm to obtain control of the opponent's body.
Associated injuries: As with other airway choke holds

POSITIONS

19. CLOSED GUARD
Definition: Most common defensive position seen on the ground. The fighter in the inferior position* wraps his/her legs around the opponent's waist and crosses his/her feet to maintain the position.

20. OPEN GUARD
Definition: The fighter in the inferior position does not lock his/her legs around the opponent's body.

21. OPEN GUARD-

22. OPEN GUARD WITH NECK CONTROL-

23. X-GUARD
Definition: Is performed by using both legs against one leg of the opponent. The leg is trapped by crossing the feet (X pattern). During this maneuver, the arms of the attacking competitor are used to off balance the other leg of the opponent.

24. X-GUARD-

25. HALF GUARD (with UNDERHOOK)
Definition: The fighter in the inferior position uses his legs to control only one leg of the fighter in the superior position.

26. HALF GUARD (with ELBOW ESCAPE)
Definition: The fighter in the inferior position uses his legs to control only one leg of the fighter in the superior position.

---

* Inferior and superior refer to POSITION, not fight advantage

27. SIDE CONTROL (aka side control or side mount)
Definition: Is a dominant position in fighting. The fighter in the superior position has cleared the legs of the fighter in the inferior position and is now perpendicular to his/her opponent, and in control of the fighter in the inferior position.

28. FULL MOUNT

Definition: Dominant position in which the fighter in the superior position has straddled the chest of the combatant in the inferior position.

29. BACK CONTROL WITH HOOKS IN: (variation of rear mount)
Definition: The fighter in the superior position has his/her opponent's back and has his/her legs hooked into the opponent's pelvic area. Alternatively, the fighter in the superior position can triangle the opponent's body (body lock) to control position.

30. NORTH-SOUTH
Definition: Both fighters are on the ground. The fighter in the inferior position is facing up, while his/her opponent is facing down. The competitors' feet are facing in opposite directions.

31. NORTH-SOUTH-

32. CRUCIFIX TO NECK CRANK
Definition: A technique that is used to control an opponent's arms. The attacking competitor uses his arms and legs to perform this technique. The neck is often hyper-flexed during this maneuver.

33. UNDER HOOKS: Photo-UNDER HOOK CLINCH
Definition: The attacker wraps his/her arm under the opponent's arm and around the opponent's shoulder area or torso.

34.OVER HOOKS: Photo-OVER HOOK CLINCH
Definition: The fighter performing the maneuver wraps both arms over the opponent's arms.

35.OVER-UNDER CLINCH
Definition: Over-under is a stand-up grappling position in which both combatants have one over hook and one under hook.

36. DOUBLE UNDER HOOKS: Photo-DOUBLE UNDER HOOK CLINCH
Definition: The fighter performing the technique wraps both arms under the opponent's arms. The hands are usually clasped in a takedown attempt.

37. THAI CLINCH (PLUMM)
Definition: Muay thai technique used to control the head with both hands around the neck on the inside of the opponent's arms.
Associated injuries: C-spine flexion injuries, acute disc avulsions.

38. THAI CLINCH*

39. SCISSOR SWEEP
Definition: Used from the guard position. The fighter in the inferior position traps the post arm, brings one leg across the abdomen of the opponent, keeps the other leg on the floor, and scissor kicks his/her legs together while pulling on his/her opponent's arm and pulling the opponent's head forward to offset the opponent's center of gravity before completing the sweep. : Used from the guard position

40. HIP HEIST (UP AND OVER)

Definition: Used from guard position. The fighter traps his/her opponent's posterior (back) arm, elevates his/her hips and rotates his/her opponent over, landing in the mount position.

41. PILE DRIVER
Definition: A move in which the aggressor grabs his/her opponent, turns the opponent upside-down, and then drops into a sitting or kneeling position, causing the opponent's head to be driven into the mat.
Associated injuries: Flexion and extension injuries of the neck, neuropraxia, paralysis.

42. FIREMAN'S CARRY
Definition: Is a technique that allows one fighter to carry his/her opponent across his/her shoulders. It is usually used as a set-up for a throw.
Associated injuries:
Aggressor: Thoracic and lumbar sprains and strains, possible acute disc herniation
Opponent: Depends on the way the competitor lands after completion of the throw.

43. WHIZZER
Definition: A wrestling technique used to control the opponent. It is an overhook that allows the aggressor to throw his/her weight into the opponent's shoulder. It is often used to set up throws.
Associated injuires:
Opponent: Shoulder injuries, wrist sprains and strains when attempting to post to break the fall.

44. WHIZZER-

45. SEOINAGI (Single Arm Throw)
Definition: It is a forward throwing technique in which one fighter is thrown over the other fighter's shoulder. This throw is common to many grappling disciplines.
Associated injuries:

- Attacker: Intercostal muscle and ligament injuries, lumbar sprains, strains and acute lumbar disc herniation.
- Opponent: If opponent falls improperly, wrist injuries, forearm injuries (sprains, strains, dislocations, fractures), elbow injuries (dislocations, UCL tears), neck injuries

46. SWITCH
Definition: It is a defensive technique used against a single leg takedown attempt to switch the position and gain control.
Associated injuries: no major associated injuries

47. ARM BAR
Definition: Definition: A straight arm lock technique that attacks the elbow hyper-extending the joint.
Associated injuries: Sprains, strains, fractures, valgus overload syndrome

48. ARM BAR-

49. DOUBLE ARM BAR

Definition: Attacks both arms simultaneously. Performed from the guard position, the athlete brings his/her legs up high around his/her opponent's back and neck area trapping both arms. The athlete extends his/her hips while controlling the opponent's wrists.
Associated injuries: As for single arm bar

50. KIMURA
Definition: Attacks both arms simultaneously. Performed from the guard position, the athlete brings his/her legs up high around his/her opponent's back and neck area trapping both arms. The athlete extends his/her hips while controlling the opponent's wrists.
Associated injuries: As for single arm bar

51. ARM TRIANGLE
Definition: Performed by trapping an opponent's arm against his/her own neck. The head is used to control the arm while the arms are wrapped around the opponent's neck and arm. Performed correctly the action intensifies when the athlete moves to an approximate 60 degree angle from his/her opponent.
Associated injuries: complications of vascular chokes, neck injuries

52. AMERICANA
Definition: Also known as a "Key Lock" attacks the shoulder area. This is usually performed in a cross body mount position. Athlete must control his/her opponent's head position while keeping the arm bent at a 90 degree angle.
Associated injuries: Shoulder dislocations, sprains, strains

53. OMOPLATA
The omoplata is a submission that attacks the shoulder area by using the legs.
Associated injuries: as Americana

54. OMOPLATA-

55. GOGOPLATA
Definition: A choke hold usually performed from the guard position. The shin is brought across the opponent's neck while one arm moves under the leg and meets up with the other arm to pull down on the opponent's head.
Associated injuries: Neck hyper-flexion injuries, airway choke, tracheal fracture

56. REAR NAKED CHOKE
Definition: Most common choke used from behind the opponent. The athlete brings his/her arm around his/her opponent's neck and locks the arm in place by grabbing his/her opposite arm at the elbow and wrapping the hand behind his/her opponent's head.
Associated injuries: Vascular choke hold: dissections, stroke (if hold applied too long), seizures

57. STÅNDING GUILLOTINE
Definition: Straight arm choke used when facing an opponent. This is usually performed from standing or guard position.

Associated injuries: Airway choke hold primarily: compression of the trachea (and larynx), tracheal fracture, subcutaneous emphysema, hypoxic brain injury and death if applied too long.

58. STANDING GUILLOTINE

59. D'ARCE CHOKE
Definition: Performed in the opposite direction from the Anaconda choke.
The arm starts from the opponent's side and moves up along the neck area and wraps into the opposing elbow.
Associated injuries: As above

60. D"ARCE CHOKE

61. D'ARCE CHOKE

62. GUILLOTINE CHOKE

63. FRONT CHOKE
Definition: Performed by placing the blade of the forearm across the neck area and grabbing the arm to fulcrum the leverage down into the throat area to create the choke
Associated injuries: As above (Guillotine choke)

64. NORTH-SOUTH CHOKE
Definition: Performed while one athlete is on top of his/her opponent with one fighter facing down and one fighter facing up. The fighter in the superior position slips his/her arm around the bottom fighter's head allowing the armpit area to settle into the throat area. The fighter in the superior position then settles his/her weigh down applying the choke.
Associated injuries: As above for both vascular and choke holds.

65. TOE HOLD with FIGURE FOUR ANKLE LOCK
Definition: Attacks the ankle joint. The competitor grabs the foot of his opponent and applies a figure four with his/her arms around the lower leg while applying pressure toward the inside of the foot.
Associated injuries: Ankle sprains, strains, dislocations, fractures.

66. TOE HOLD with FIGHURE FOUR ANKLE LOCK

67. TRIANGLE
Definition: The triangle choke is usually applied from the guard position. The attacking athlete passes one leg over his/her opponent's shoulder trapping the head and one arm inside. The attacking athlete applies a figure four with his/her legs, which forces the trapped arm to apply pressure against the neck.

Associated injuries: Hyperflexion injuries of the head, vascular choke complications.

68. ELEVATOR SWEEP

Definition: Used from the guard position. The fighter performing the maneuver hooks the inside of the opponent's leg with his/her foot. The fighter then pulls the opponent towards him/her while lifting the opponent with the hooked leg. The opponent is rolled over the shoulder area to complete the sweep.
Associated injuries:
Opponent: flexion or extension injuries of the neck

69. ELEVATOR SWEEP

70. DOUBLE ANKLE SWEEP
Definition: The fighter in the superior guard position stands up. The fighter in the inferior position drops his/her closed guard and grabs the standing fighter's ankles. The fighter in the inferior position places his knees in the opponent's abdomen, raises his/her hips and pushes the standing fighter over following the movement until he/she gains top position.*
Associated injuries:
Opponent: hip flexor injuries, lumbar sprains and strains.

71. DOUBLE ANKLE SWEEP